



Case Report

# Nasal Reflux Management of Obturator in Dentate Maxillectomy Patients

Ariyanti Rezeki<sup>1§</sup>, Pinta Marito<sup>1</sup>

<sup>1</sup> Department of Prosthodontic, Faculty of Dentistry, Universitas Indonesia, Indonesia

Received date: June 24, 2020. Accepted date: September 5, 2020. Published date: October 30, 2020.

## KEYWORDS

maxillary defect;  
nasal reflux;  
obturator;  
retention;  
stability;  
support

## ABSTRACT

**Introduction:** Maxillary defects are probably the most common of all intraoral defects. Moreover, their size and location affect the degree of difficulty in prosthetic rehabilitation. Maxillary defects may be divided into two types: (i) defects resulting from congenital malformations and (ii) acquired defects resulting from surgery for oral neoplasms. Acquired maxillary defects in the form of postsurgical defects can cause conditions such as nasal voice (hypernasal speech), nasal cavity leakage, mastication function deterioration, and considerable facial collapse due to extensive bone loss. **Case Report:** A 34-year-old male patient with resection—without prior surgical or interim obturator placement—performed in 2018 on the premaxillary segment and anterior maxillary alveolar ridge came to the Department of Prosthodontics, Faculty of Dentistry, Universitas Indonesia (Depok, Indonesia). The prosthetic rehabilitation goals for this case included the separation of oral and nasal cavities to allow adequate deglutition and articulation, possible support of the orbital contents to prevent enophthalmos and diplopia, support of the soft tissue to restore the midfacial contour, and an acceptable aesthetic result. In this clinical report, a maxillary obturator prosthesis framework was used as a definitive treatment. **Conclusion:** A proper and detailed treatment sequence is critical for successful prosthetic rehabilitation of a dentate maxillectomy patient. A considerably successful maxillary obturator indicator, such as masticatory function and distinct speech, was regained. The nasal cavity leakage problem was solved after sealing the gap between the oral and nasal cavities by providing adequate extensions of the flange.

<sup>§</sup> Corresponding Author

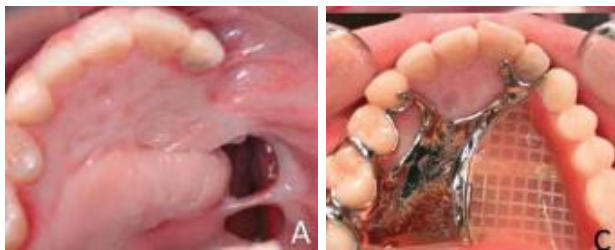E-mail address: [ariyanti.rezeki@gmail.com](mailto:ariyanti.rezeki@gmail.com) (Rezeki A)

DOI: [10.32793/jida.v3i2.590](https://doi.org/10.32793/jida.v3i2.590)

**Copyright:** ©2020 Rezeki A, Marito P. This is an open access article distributed under the terms of the Creative Commons Attribution License, which permits unrestricted use, distribution, and reproduction in any medium provided the original author and sources are credited.

## INTRODUCTION

An obturator (or obturate in Latin) is an artificial disk or plate used to close the congenital gaps or defects resulting from the surgery for cleft palate and partial or total maxillary resection for malignant or benign tumors.<sup>1</sup> The obturator has several functions, such as facilitating speech, allowing deglutition, improving articulation, and restoring mastication.<sup>2</sup> Fig. 1 shows an example of a maxillary defect and maxillofacial prosthesis. Maxillary defects are caused by the surgical treatment of benign or malignant neoplasm or by trauma. The local and regional spread of the disease is controlled with maxillary and palatal resection, but it results in open communication between the oral and nasal cavities.<sup>3</sup>



**Figure 1.** Maxillary defect and maxillofacial prosthesis

Postsurgical complications often occur after the removal of neoplasms from the maxilla region. The most common complications of the maxilla include hypernasal speech, nasal reflux, and impaired masticatory function. Complications associated with nasal function are among the most encountered complaints following the insertion of an obturator.<sup>4</sup> Nasal reflux is the leakage into the nose caused by the escape of air. It can cause fibrosis in the tissue bordering the prosthesis or loss of lip support, and it may occur several months after the insertion. Design considerations include the closure of the oral cavity, provision of a stable base to regain function, restoration of midface symmetry, and provision of support to orbital structures.<sup>2</sup> A successful prosthetic design utilizes the remaining palate and dentition to maximize support, stability, and retention. Satisfactory obturation of the maxillary defect is evaluated by production of speech and absence of nasal cavity leakage during swallowing.<sup>5</sup>

Hypernasal speech is the sound of speech that results from a significantly large amount of air escaping through the nose while talking. There are certain letters and sounds that should not have air passing through the nose during speech. Examples include all vowels and consonants such as *s*, *b*, and *k*. To keep this from happening, the roof of the mouth (velum) must touch the back of the throat (pharynx). If they do not touch correctly, this results in an incomplete seal of this area, and a good amount of air passes through the nose,

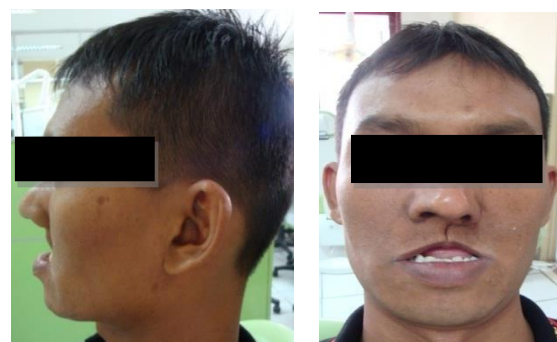resulting in hypernasal speech. This is known as *velopharyngeal incompetence*. Hypernasal speech can be caused by anything resulting in velopharyngeal incompetence. Other than surgical approaches, such as pharyngoplasty or palatoplasty, obturation and speech therapy may all be necessary for some forms of hypernasal speech.

## CASE REPORT

### Clinical Case Description

A 34-year-old male patient presented to the Department of Prosthodontics, Faculty of Dentistry, Universitas Indonesia (Depok, Indonesia), with chief complaints of impaired masticatory function, nasal reflux, and hypernasal speech. The patient's dental record conveyed that a resection procedure without the placement of a surgical or interim obturator was performed 2 years ago on the premaxillary segment and anterior maxillary alveolar ridge. The extraoral examination, as shown in Fig. 2, revealed that the loss of lip support caused contracture and shortening of the upper lip. Also, there was nasal cavity leakage during swallowing and rinsing.

The intraoral examination, as in Fig. 3, showed a maxillary defect in the anterior palate region leading to the nasal cavity floor. The diameter of the defect was 15 mm, and it was classified as being "class VI" according to the Aramany classification. There were multiple missing teeth, including 13, 12, 11, 21, 22, 23, 24, and 25. Unstable occlusion with remaining teeth and group function articulation were present on both sides. Bad oral hygiene was noted. The remaining maxillary teeth were occluded with the mandibular teeth. There were extensive caries on 18 and enamel caries on 28. Posterior overjet of 2.0 mm and overbite of 2.5 mm were noted. Panoramic imaging, as shown in Fig. 4, revealed the loss of maxillary bones and alveolar bones from 13, 12, 11, 21, 22, 23, 24, and 25, with a crown and root ratio of 1:2 on the remaining teeth.



**Figure 2.** Patient's profile from lateral and frontal view

## Treatment Planning

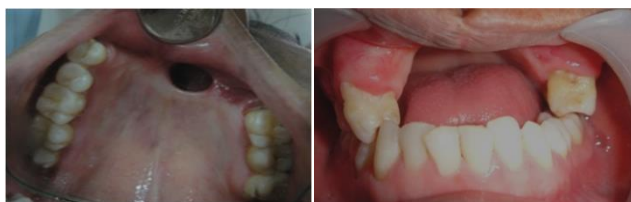A cast framework obturator was selected for this case to gain support from the remaining teeth and residual hard palate. Furthermore, retention was achieved from the retainer on the abutment teeth, denture base extension, alveolar ridge, and lip support. The treatment sequence began with pre-prosthetic phases, including scaling, extraction of 18, and direct restoration of 28. A primary impression was taken using a stock tray and irreversible hydrocolloid impression material. After obtaining the primary cast followed by the survey and design procedure, abutment rest preparation was performed on 14, 16, 17, 26, and 28. The initial framework design is shown in Fig. 5: major connector using full palate, direct retainer: RPY bar on 14, double akers on 16 and 17, and akers on 26–28.

Then, with the border molding technique using a green stick compound, the defect's extent was recorded. This was followed by the final impression to obtain a master cast. The cast framework obturator was fabricated in the dental laboratory, and the procedure continued with a try-in framework, as shown in Fig. 6. After evaluating the framework, intermaxillary relationship records were taken, as shown in Fig. 7. Obturator processing continued with teeth arrangement (Fig. 8).

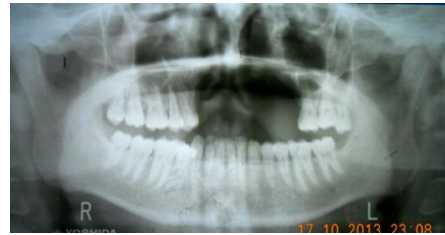The cast framework obturator was delivered, evaluation of functional mastication was performed, and deglutition function was regained. However, leakage occurred when the patient gargled, causing the water to come down from the nasal cavity. To overcome this problem, the operator relined the framework using a soft liner and instructed the patient to wear the obturator during function and sleep (Fig. 9)

## Post-delivery Control 1

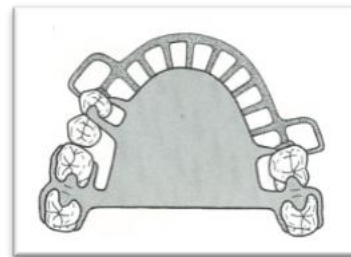The patient felt pain in the upper left posterior vestibulum area. On clinical examination using a pressure indicating paste, there was redness noted in the vestibulum area, and grinding and polishing were performed in that area. The patient was able to wear the obturator to eat, drink, and speak smoothly, but there was still a minor issue of nasal cavity leakage when the



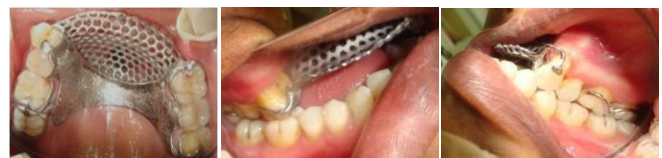**Figure 3.** Maxillary defect from occlusal and frontal view.



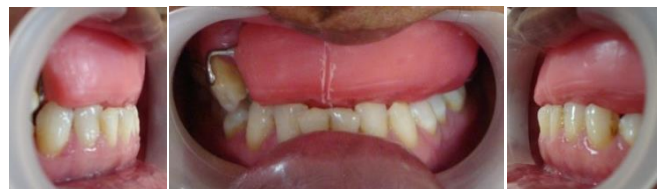**Figure 4.** Panoramic image



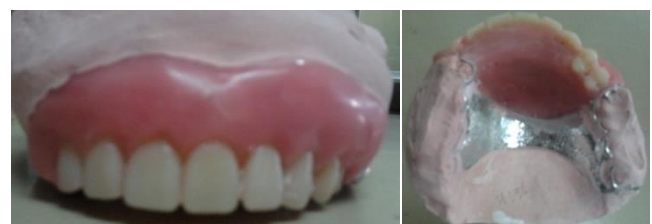**Figure 5.** Major connector using full palate, direct retainer: RPY bar on 14, double akers on 16 and 17, and akers on 26–28.



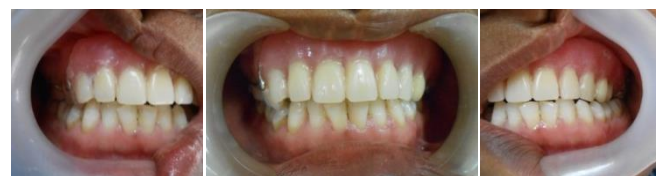**Figure 6.** Try-in framework



**Figure 7.** Intermaxillary relationship records



**Figure 8.** Teeth arrangement on frontal and occlusal view.



**Figure 9.** Insertion of cast framework obturator

patient gargled. This may have caused the collapse of the orbicularis oris muscle, leading the water from the nasal cavity to leak through the labial extension of the obturator base. A soft denture liner was used to seal the nasal cavity leakage, as shown in Fig. 10. However, it lasted only a few days, and the leakage happened again. The operator, then, needed to make a functional impression using a green stick compound, as shown in Fig. 11, to overcome the existing leakage problem. The functional impression was taken to support the buccal area affected by the collapse of the orbicularis oris muscle. This impression was then sent back to the laboratory.

## Post-delivery Control 2

The remaining complaint about nasal cavity leakage was finally resolved, and all function was adequately regained. Patient occlusion and articulation were evaluated thoroughly. The patient was satisfied with this last modification. Fig. 12 shows a comparison of the patient's profile before and after the insertion of the obturator.

## DISCUSSION

The direct effect of maxillary defects that are caused by the surgical intervention of neoplasms profoundly affects functional abilities. The maxillary defect that causes functional disability because of oral and sinonasal cavity communication can be restored by prosthetic replacement with a pressure resistance seal of an obturator bulb against the mucosal lining and skin graft covering the defect.<sup>3</sup>

In this case, the anterior palate defect passed the midline and was classified as class VI according to the Aramany classification. (Fig. 13) The class VI defect is a rare surgical creation. It mostly results from a congenital anomaly or trauma—such as an automobile accident or a self-inflicted wound that removes the entire premaxillae (and may include a portion of one or both maxillae), leaving a single bilateral defect located anterior to the remaining teeth. Surgical defects of this nature are usually small. Nonsurgical defects are usually large and difficult to manage.<sup>6</sup>

A successful obturator design can be obtained if we pay attention to three factors: (i) support, (ii) retention, and (iii) stabilization. Support is defined as the resistance to the vertical forces during mastication and swallowing (resistance to prosthesis movement toward the tissue). Support can be achieved from the residual maxilla, remaining teeth (periodontal status, splinting, and rest), alveolar ridge (size and shape—square or ovoid shapes are better than tapered), and residual hard palate.

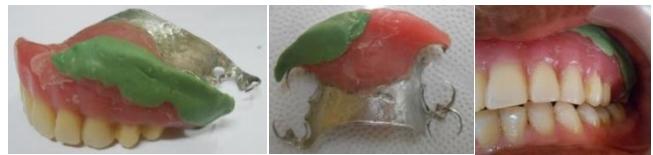


Figure 11. Functional impression

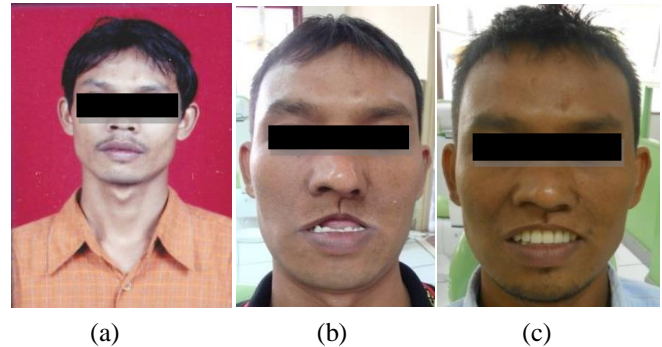


Figure 12. (a) before trauma; (b) 2 years after surgery; and (c) after insertion of obturator

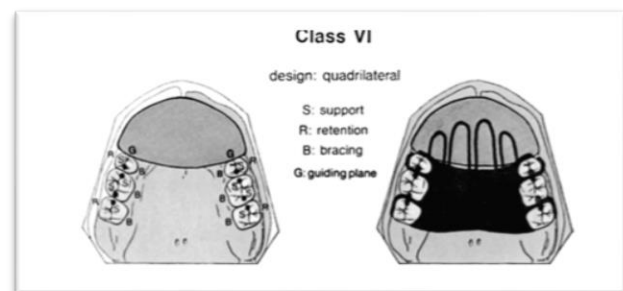


Figure 13. Aramany class VI design<sup>6</sup>

Meanwhile, from within the defect, we can also gain support from the floor of the orbit, pterygoid plate or temporal bone, and nasal septum.<sup>2</sup>

The retentive design is critical in the maxillectomy patient who has lost extensive supportive and retentive structures. Every component of the removable partial denture framework must be used to maximize both retention and stability.<sup>7</sup> In this case, retention provided with Y-bar located on the anterior abutment teeth in a midfacial undercut close to the fulcrum line could function effectively. Combination retainers may also be used on the anterior abutments teeth for aesthetic reasons or when protection of the anterior abutments is considered. Effective accessory retention can also be achieved by extending the prosthesis anteriorly into the nasal aperture. Cosmetic support of the nose and upper lip is also possible when adequate retention is present.

Patients wearing obturators over a long time complain of nasal reflux and hypernasal speech caused by the escape of air. Nasal reflux is a common problem that is usually experienced by patients who have had a

maxillectomy. It is caused by continued fibrosis in the tissue bordering the prosthesis or loss of lip support. The difficulty of lip closure caused by contracture and shortening of the upper lip usually happens when a surgical procedure is performed without the placement of a surgical obturator. The obturator should be coated with tissue conditioning material, and the patient should be instructed to perform functional movement to enhance the peripheral seal. In some instances, when the lip support is not adequate, second border molding is needed to get adequate denture base extensions.<sup>8</sup>

If swallowing and speech improve, the tissue conditioning material should be evaluated for the area where the tissue conditioner is thickest. Speech can be tested by evaluating the *m* and *b* sounds and the word beat. The thickness of the material can be checked with an explorer.

Most areas will be very thin, while other areas will be 2–3 mm or thicker. These thicker areas should be targeted for the relining procedure, which can be accomplished on the chair side with an autopolymerizing or composite acrylic resin. This procedure satisfied the patient's chief complaint and required minimal time.<sup>8</sup>

The most common treatment option would be to close the defect with an obturator, which recreates a partition between the oral and nasal cavities and adequate extensions of the flange, thereby improving speech articulation and reducing nasal reflux. Proper obturator function has been reported to account for improved quality of life.<sup>9,10</sup>

## CONCLUSION

Prosthodontic rehabilitation of patients with maxillofacial defects involves a multidisciplinary treatment requiring a lengthy and involved process from clinicians and patients themselves. Hence, proper sequencing and details of the treatment need to be reviewed carefully in order to provide the best result.

## DECLARATION OF PATIENT CONSENT

The authors certify that they have obtained all appropriate patient consent forms. In the form, the patient has given his consent for his images and other clinical information to be reported in the journal. The patient understands that his name and initials will not be published and due efforts will be made to conceal identity, but anonymity cannot be guaranteed.

## CONFLICT OF INTEREST

There is no conflict of interest of this study.

## REFERENCES

1. Keyf F. Obturator prostheses for hemimaxillectomy patients. *J Oral Rehabil.* 2008;28(9):821-829. doi:10.1111/j.1365-2842.2001.00754.x
2. Beumer J, Marunick MT, Esposito SJ. *Maxillofacial Rehabilitation: Prosthodontic and Surgical Management of Cancer-Related, Acquired, and Congenital Defects of the Head and Neck.* Quintessence Pub, Chicago, USA. 2011.
3. Vero N, Mishra N, Singh BP, Singh K, Jurel SK, Kumar V. Assessment of swallowing and masticatory performance in obturator wearers: a clinical study. *J Adv Prosthodont.* 2015;7(1):8-14. doi:10.4047/jap.2015.7.1.8
4. Islam MS, Rahman MM, Islam P, Hayet ASM, Rahman SA, Azam MS. Influences of Size and Form of Maxillectomy Defect, and Remaining Maxillary Teeth on Oral Functions of Patients Receiving Prosthetic Therapy with Obturator. *Int J Dent Med.* 2015;1(1):1-7.
5. Parr GR, Tharp GE, Rahn AO. Prosthodontic principles in the framework design of maxillary obturator prostheses. *J Prosthet Dent.* 1989;62(2):205-212.
6. Parr GR, Tharp GE, Rahn AO. Prosthodontic principles in the framework design of maxillary obturator prostheses. *J Prosthet Dent.* 2005;93(5):405-411. doi:10.1016/j.prosdent.2005.02.017
7. Martin JW, King GE. Framework retention for maxillary obturator prostheses. *J Prosthet Dent.* 1984;51(5):669-672.
8. Bhandari AJ. Maxillary obturator. *J Dent Allied Sci.* 2017;6(2):78-83. doi:10.4103/jdas.jdas\_25\_17
9. Depprich R, Naujoks C, Lind D, Ommerborn M, Meyer U, Kubler NR, et al. Evaluation of the quality of life of patients with maxillofacial defects after prosthodontic therapy with obturator prostheses. *Int J Oral Maxillofac Surg.* 2011;40(1):71-79. doi:10.1016/j.ijom.2010.09.019
10. Irish J, Sandhu N, Simpson C, Wood R, Gilbert R, et al. Quality of life in patients with maxillectomy prostheses. *Head Neck.* 2009;31(6):813-821. doi:10.1002/hed.21042