

Remodeling tulang: sukses klinis saat autotransplantasi gigi disertai penambahan bahan cangkok tulang

Heru Maksmara

Rumah Sakit Pangkalan Udara Adi Soemarmo, Solo

Abstrak

Suksesnya perawatan periodontal adalah adanya regenerasi struktur jaringan periodontal; diantaranya pertumbuhan tulang yang baru, sementum, dan pertumbuhan baru serat jaringan periodontal. Telah banyak dilaporkan kesuksesan penggunaan bahan cangkok tulang, sebagai bahan pengganti yang akan mempelopori pertumbuhan jaringan formasi tulang yang baru, dikenal remodeling. Regenerasi periodontal adalah proses migrasi ke defek periodontal secara proliferasi serta diferensiasi sel – sel periodontal. **Penatalaksanaan.** Seorang laki – laki umur 14 tahun mengalami trauma pada rahang atas anterior. Pemeriksaan ekstra oral ia mengalami memar pada bibir atas dan juga berdarah. Rontgen panoramik menampakkan adanya kerusakan tulang yang hebat. Gigi 21 dan 22 terlepas dari tulang, kegoyahan gigi 4⁰, kehilangan perlekatan klinis pada gusi labial dan mukosa palatal, dan kedalaman probing 8 – 12 mm. Pasien tidak menghendaki kehilangan gigi, sehingga tidak memerlukan menggunakan gigi tiruan. Gigi yang terlepas dari tempatnya dicabut, dibersihkan dengan larutan salin, serta dilakukan perawatan saluran akar. Daerah operasi juga dibersihkan dengan menggunakan larutan salin, sewraya mengatur kembali serpihan tulang fraktur. Guna remodeling tulang, bahan cangkok tulang yang dipergunakan; *demineralized freeze-dried bone allograft* (DFDBA). Gigi yang akan ditanam kembali, reimplantasi, harus di splinting dengan baik. Pasien harus menjaga kebersihan mulutnya, tidak mengunyah makanan pada gigi reimplantasi, juga mematuhi jadwal kontrol. Kesuksesan perawatan ditentukan dari data kedalaman probing, derajat kegoyahan gigi, perdarahan saat probing, perlekatan klinis, dan data diambil sebelum dan sesudah 6 bulan operasi. Bila diperlukan, dapat dilakukan re-entry / operasi ulang. **Hasil.** Setelah enam bulan paska operasi. Tidak terjadi perdarahan saat probing, juga kegoyahan gigi, kedalaman probing semula 10 – 15 mm menjadi 3 – 4 mm.

Korespondensi:

Heru Maksmara

Rumah Sakit Pangkalan Udara
Adi Soemarmo, Solo

Setelah 9 bulan splin dapat dilepas. **Kesimpulan.** Dengan minimnya pengalaman yang didapat, diambilnya tindakan autotransplantasi gigi paska trauma dapat mempertahankan gigi tetap ditempatnya dengan tehnik remodeling tulang disertai penambahan bahan cangkok tulang DFDBA.

Kata kunci: bahan cangkok tulang, demineralisasi freeze-dried tulang allograft, remodeling tulang, osseointegrasi, autotransplantasi gigi.

Abstract

The primary goal of periodontal treatment is regeneration of the supporting periodontal structures: i.e., formation of new bone, cementum, and new periodontal ligament collagen fibers. Successful using bone graft are many reported as bone replacement material promoting new bone formation, remodeling. Periodontal regeneration may be achieved by migration into periodontal defects and proliferation and differentiation of periodontal cells. **Implementation.** 14 year old young boy got trauma in his anterior upper jaw. Extra oral examination he got brushess of upper lip and bleeding. Panoramic view shows bone fracture. His teeth of 21 and 22 got lost connections with bone, tooth mobility 4⁰, lost clinical attachment of gingiva and palatal mucosa, and 8 - 12 mm of probing depth. Patients who experience head trauma around face, want to keep teeth in place as before, and do not require the use of prostheses. Teeth which are detached from the socket and experience shakiness 4⁰ in extraction and cleaned using saline solution, and got a root canal treatment. Areas of trauma also be cleaned with saline solution and arranged the bone fragments. For bone remodeling, bone graft material may be used; demineralized freeze-dried bone allograft (DFDBA). Teeth in reimplantation must be splinted well. Patients should have good oral hygiene and do not consume food in the form of dense and chewy, and obey the traffic control. The success is determined by the parameters of probing depth, shakiness tooth, bleeding on probing, clinical attachment level, data taken before surgery and after six months of operation, if it is necessary, re-do the operation anyway. **Results.** After sixth month operation. There is no bleeding on probing and dental shakiness after six months of operation, and decreasing of probing depth of 10-15 mm to 3-4 mm. After 9 month of splint can be off. **Conclusions.** With all the limitations of experience, in this research can be concluded that we can maintain post-

traumatic tooth in place of autotransplants technique by the periodontal tissue remodeling technique by using the additional of DFDBA bone graft material.

Key words: bone graft materials, demineralized freeze-dried bone allograft, bone remodeling, osseointegration, autotransplant of the teeth.

Pendahuluan

Many approaches are used to repair skeletal defects in reconstructive orthopaedic surgery, and bone grafting is involved in virtually every procedure. An elegant cellular and molecular cascade follows bone transplantation. Bone graft incorporation within the host, whether autogenous or allogeneic, depends on many factors: type of graft (autogenous versus allogeneic, vascular versus nonvascular), site of transplant, quality of transplanted bone and host bone, host bed preparation, preservation techniques, systemic and local disease, and mechanical properties of the graft. The type of bone graft used depends on the clinical scenario and the anticipated final outcome. Autogenous cancellous bone graft, with its osteogenic, osteoinductive, and osteoconductive properties, remains the standard for grafting.¹ Bone graft is necessary when there is not enough jaw bone structure to support the placement of one or more implants and provide sufficient strength and stability. The success of autotransplants of the teeth depends significantly on the existence of adequate jaw bone around the transplant. The bonding of the implant to the jaw can be succeeded only when there is a critical mass of healthy jawbone to trigger and maintain the osseointegration process.^{1,2} Many patients who want to replace missing teeth with autotransplants of the teeth learn from their dentists that they are not suitable candidates for autotransplants due to the poor condition of the bone in their jaws. Without a procedure

such as bone graft their only alternative are conventional bridges or dentures. Autotransplant by adding bone grafting can restore the lost bone and allow them to have new completely functional teeth.¹⁻³

Bone graft procedures are performed usually to correct existing bone loss problems in preparation of autotransplant placement. Some times the dentist will perform a bone graft immediately after a tooth extraction to fill the extraction site and prevent the bone loss around it.^{1,2} Replacement of missing bone structure with transplant bone graft can be the critical factor between autotransplant success and transplant failure. Researches indicate that bone grafting can reduce the risk of transplant complications.^{1,3}

Jaw bone loss is in most cases caused either due to missing teeth or because of severe periodontal disease. In general, you may need dental bone grafting in case of ;¹

missing teeth - Bone maintains its structure and volume through mechanical stimuli. When a tooth is lost, the mechanical stimulus is also lost; the body thinks that the bone is no longer needed there and starts the resorption process to recover the bone minerals. This condition can lead to poor quality and quantity of bone making patients not suitable candidates for placement of dental implants. People who have been edentulous (without teeth) for a prolonged period are the more seriously affected.

periodontal disease - Infections of the periodontium trigger a response from the body's immune system. Specialized cells called phagocytes attack the infected tissues,

gums, periodontal ligament and jawbone, in an effort to eliminate the infection. The process can lead to severe loss of jaw bone structure if the periodontal disease is not treated successfully. Not only existing teeth may be lost but the ability of replacing them with dental implants is also decreased.

injury - Other conditions that dental implant bone grafts are needed include injury or trauma and some developmental defects that affect the bone growth pattern. Autotransplant of the teeth by adding bone grafting is a surgical procedure performed to replace missing bone with a bone graft and help the body regrow new bone in implantation areas with severe bone loss or bone damage. Bone grafting is usually part of a bone augmentation process that could also involve Guided Bone Regeneration (GBR).^{1,2,3,4} Missing teeth can affect;^{1,2,3}


Appearance - Even if a single front tooth is missing, it can seriously affect the person's appearance, self esteem and social life. With today's standards in developed countries it is not socially expected to show a missing tooth when talking or smiling. To keep natural teeth stayed in jaw is better than any other alternative dentures.

Eating - Missing several teeth can reduce the ability to eat certain food groups,

resulting in bad nutrition and poor quality of life. Dental implants restore the full functionality of your mouth, and you can return to your favorite diet enjoying life just like with natural teeth.

Speaking - The absence of one or more teeth can disturb your speech, cause a lisp and change the way your voice sounds. That's very comfortable to keep regular teeth stayed without causing the speech problems that are common when teeth are missing or dentures are used, especially removable ones.

Bone graft description. It may consists of osteoinductive Demineralized Bone Matrix (DBM) and osteoconductive cancellous bone chips. Using bone allograft allows you to avoid autograft procurement and associated morbidity risks. Also, because it not only provides osteoconductive scaffold but also native, osteoinductive growth factors " Bone Morphogenetic Proteins " (BMPs), you will achieve faster and stronger bone healing compared with using bone substitutes. The demineralization of allograft during tissue processing allows for immediate access to the growth factors (BMPs) inherent in natural bone when it is placed into the surgery site. This results in an immediate beginning of the healing process and helps to make allograft as effective as autograft.^{2,3,4,5}

<p>Powder of Bone Graft:</p>		
<p>Particle Size:</p>	<p>Demineralized Bone Matrix with cancellous chips < 2.3 mm</p>	<p>Demineralized Bone Matrix with cancellous chips < 0.7 mm</p>
<p>Indications:</p>	<p>Fracture voids Mal- or non-unions Bone loss cases TPLOs and TTAs</p>	<p>Fractures with no voids Small breeds Arthrodeses Hip implants</p>
<p>Preservation:</p>	<p>Freeze-Dried or Frozen</p>	<p>Freeze-Dried</p>

Type of bone graft⁴

The major problem of bone loss, beyond the apparent aesthetic ones, is that any remaining teeth will eventually become loose and fall out, and that dentures will be hard to fit because there will be not enough bone to support them. Dental implants can act as the natural tooth roots providing the necessary pressure to the bone and preventing further bone loss.^{5,6} This study offering dentist to do autotransplantation of the teeth with many thing advantages solven. The patient, who got maxillofacial trauma shouldn't get missing teeth and using dentures anymore, but keep wisely case to do this Why graft: ⁴⁻⁸

Bone remodeling will heal faster when voids are filled with bone graft, because it provides osteoconductive scaffold for host bone to grow on and native, osteoinductive BMPs that attract osteoblasts to the site. Even when there are no voids, bone graft provides these same advantages.

Faster healing not only gets your patients back to normal activity faster it also increases the chances of a successful healing outcome. Why use allograft:^{4,5,6,7,8}

Eliminates morbidity risks associated with the collection of bone autograft. In many cases, allows you to use more bone graft than you can procure from the patient. Allograft can also be used to augment insufficient quantities of autograft. Studies show that allografts are as effective as autograft in bone healing. Achieves faster and stronger bone healing than bone substitutes due to osteoinductive growth factors (BMPs) inherent in natural bone. Bone modeling happen.

Case report

14 year old young boy got trauma in his anterior upper jaw. Extra oral examination he got brushness of upper lip and bleeding. Panoramic view shows bone fracture. His

teeth of 21 and 22 got lost connections with bone, tooth mobility 4⁰, lost clinical attachment of gingiva and palatal mucosa, got bleeding on probing, and 8 - 12 mm of probing depth. 11 and 23 are tooth mobility 2⁰. Patients who experience head trauma around face, want to keep teeth in place as before, and do not require the use of prostheses. Teeth which are detached from the socket and experience shakiness 4⁰ in extraction and cleaned using saline solution, and got a root canal treatment.^{5,6,7,8,9,10} He got labial and palatal upper left bone fracture. Areas of trauma also be cleaned with saline solution and arranged the bone fragments. For remodeling bone graft material may be used DFDBA.

Patient must obey control time once a month at least, to keep oral hygiene in good condition. Nine month after operations there is no tooth mobility happen, no bleeding on probing, 3 - 4 mm of probing depth, and gingiva is in better condition with larger clinical attachment level. So if there is no compliments condition of teeth problem, such like chewing, articulation, speech, or else the splint can remove. The teeth back to normal.

Discussion

The factors contributing to a delayed union or nonunion are many. In general they may be divided into three major categories: deficiencies in vascularity and angiogenesis, deficiencies in the robustness of the chondroosseous response, and deficiencies in stability, strain, or physical continuity. Frequently, deficiencies in more than one category are present, thus complicating the approach to therapy. For a bone grafts to enhance fracture healing, it must provide or stimulate that which is deficient. Autogenous fresh cancellous and cortical bone most frequently are used, but other common grafts include allogeneic frozen, freeze

dried, or processed allogeneic cortical, corticocancellous and cancellous grafts, and demineralized bone matrix. These grafts have varying capacities to provide active bone formation, to induce bone formation by cells of the surrounding soft tissue, and to serve as a substrate for bone formation. However, the graft cannot exert its biologic activity in isolation, dependent as it is on the surrounding environment for cells to respond to its signals and, in some cases, for blood supply. The mechanical environment of the graft site is also important. Successful graft incorporation requires that an appropriate match must be made between the biologic activity of a bone graft, the condition of the perigraft environment, and the mechanical environment. The task of the clinician who performs a bone grafting procedure for the enhancement of fracture healing is to choose the right graft or combination of grafts for the biologic and mechanical environment into which the graft will be placed.^{1,3,7,9}

Recent investigations have explored how analyses of genetic DNA from organ donors and recipients may be helpful during organ allocation so as to reduce graft rejection or improve dosing of immunosuppressive medications. This discussion reviews those data and the processes by which genetic coding controls the production of protein that is important in cellular structure and function during donor and recipient care. Changes in gene structure (polymorphisms or mutations) may occur spontaneously or as a result of cell interactions with environmental factors, and may be associated with recognized diseases or, potentially, could reduce or worsen graft rejection.^{8,9,10}

Many approaches are used to repair skeletal defects in reconstructive orthopaedic surgery, and bone grafting is involved in virtually every procedure. The type of bone graft used depends on the clinical scenario and the anticipated final outcome. Autogenous cancellous bone graft, with its osteogenic,

osteoinductive, and osteoconductive properties, remains the standard for grafting. However, the high incidence of morbidity during autogenous graft harvest may make the acquisition of grafts from other sources desirable. The clinical applications for each type of bone graft are dictated by the structure and biochemical properties of the graft. An elegant cellular and molecular cascade follows bone transplantation. Bone graft incorporation within the host, whether autogenous or allogeneic, depends on many factors: type of graft (autogenous versus allogeneic, vascular versus nonvascular), site of transplant, quality of transplanted bone and host bone, host bed preparation, preservation techniques, systemic and local disease, and mechanical properties of the graft.^{1,3,5,7,9,11}

Contemporary allograft and synthetic grafting composites are being developed to optimize and surpass the native qualities of autogenous sources (ie, osteogenesis, osteoinductivity, osteoconductivity). Careful comparison of the cost of these alternative sources with the physical and monetary costs of autogenous bone graft will undoubtedly make allograft, recombinant, synthetic graft composites the logical choice in the very near future.^{3,6,7,8,9,10}

Conclusion.

All other classic alternative methods for restoring lost teeth such as dental bridges and dentures, and dental implants have several disadvantages compared to autotransplants. Dental bridges can prevent the adjacent teeth from shifting but they can not stop bone loss. Only dental implants can prevent bone loss caused by missing teeth.^{8-11.}

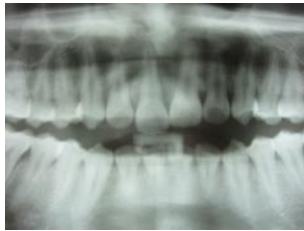
But if you want to restore the aesthetics, functionality and feeling of your avulsion teeth, autotransplants are the only solution that can provide them all. They are the benefits solution you can get to natural teeth. Affordable autotransplants of the teeth

Heru Maksmara: Remodeling tulang: sukses klinis saat autotransplantasi gigi

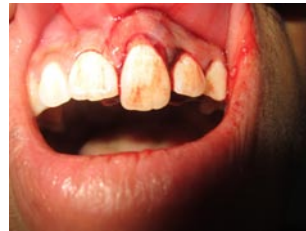is a common quest for patients with limited budget. The high cost of dental implants is the biggest obstacle for patients with

missing teeth who seek for a permanent, economics and effective solution with the use of autotransplants of the teeth.^{2-6,10,11}

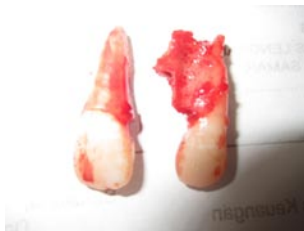Type of



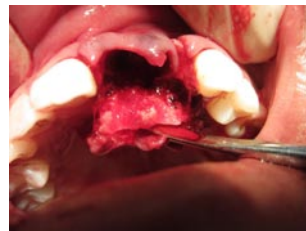Picture 1. Panoramic views



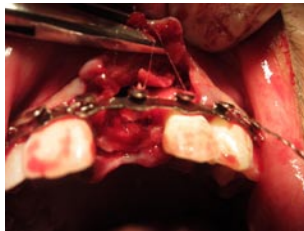Picture 2. Anterior upper views.



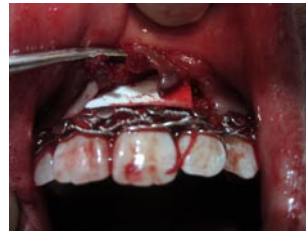Picture 3. Upper left teeth 21 and 22.



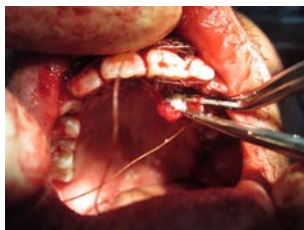Picture 4. Palatal bone fracture.



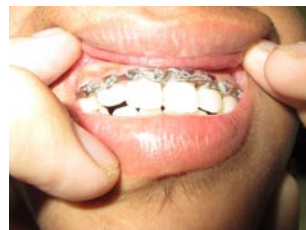Picture 5. Labial bone damage



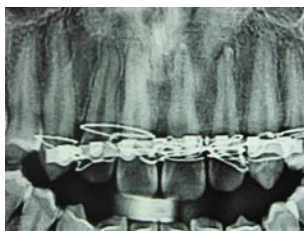
Picture 6. The bone graft and splint.



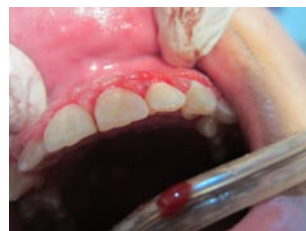Picture 7. Suture and bone graft



Picture 8. 3 month after operation.



Picture 9. 9 month panoramic views.



Picture 10. Results.

Daftar Pustaka

1. Khan, Cammisa, Shandu, Diwan, Giardi, and Lane, *The biology of bone grafting*, Dept of ortho surg, The Univ of California, Davis, J Am Acad Orthop Surg, 2005, jan-feb, 13(1) : page 77-86.
2. Misch and Dietsh, *Bone – grafting materials in implant dentistry*, Implant Dent, 1993,2(3): page 158-167.
3. Hoexter, *Boneregeneration graft materials*, J Oral Implantol, 2002;28(6):290-4.
4. Boden, *Bone repair and enhancement clinical trial design. Spine applications*. Clin Orthop Relat Res, 1998 (335 suppl): s336-46.
5. Bignon, *Effect of micro and macroporosity of bone substitutes on their mechanical properties and cellular response*, J Mater Sci Mater Med, 2003;14(12):1089–97.
6. Mastrogiacomo, *Role of scaffold internal structure on in vivo bone formation in macroporous calcium phosphate bioceramics*, Biomaterials, 2006;27(17):3230 – 7.
7. Mankani, *In vivo bone formation by human bone marrow stromal cells: effect of carrier partical size and shape*, Biotechnol Bioeng, 2001;72(1):96 – 107.
8. Jensen, *Tissue reaction and materials characteristics of four bone substitutes*, Int J Oral Maxillofac Implants, 1999;14(3):361 – 368.
9. Kubler, *Growth and proliferation of human osteoblasts on different bone graft substitutes: an in vitro study*, Implant Dent, 2004, 13(2): page 171 – 179.
10. Woodard, *The mechanical properties and osteoconductivity of hydroxyapatite bone scaffolds with multi-scale porosity*, Biomaterials, 2007, 28(1): page 45 – 54.
11. Krebsbach, *Bone formation in vivo: comparison of osteogenesis by transplanted mouse and human marrow stromal fibroblasts*, Transplantation, 1997, 63(8): page 1059 – 1069.