



Radiographic appearance of ossifying fibroma in the left mandible: a case report

Mahindra Awwaludin Romdlon^{1,2*}, Farina Pramanik³ , Achmad Mauludin⁴

ABSTRACT

Objectives: This article reports on ossifying fibroma (OF) which was established based on panoramic radiographic, CBCT and histopathological examination and treatment performed on a 31 years old male patient. The diagnosis is made by comparing with existing theories in the literature.

Case Report: A 31 years old man was referred to the Oral Surgery Department of Al Ihsan Hospital. The patient complained of swelling in the lower left jaw. On palpation it feels hard and cannot be moved. Panoramic radiograph examination showed loss of teeth 34-35 and a radiolucent lesion mixed with radiopaque in the left mandible which resulted in a shift in the position of teeth 36 and 37 more superiorly. The CBCT examination performed revealed a mixed radiolucent and radiopaque lesion of teeth 33-38. Histopathological examination also

showed the presence of cellular fibrous with a mineralized component. The patient has been treated in the form of excision of the lesion.

Conclusion: CBCT can be used as a reliable supporting examination in helping to diagnose cases of benign neoplasms involving hard bone tissue such as ossifying fibroma. OF has distinctive features on radiographs, one of which is the presence of mixed radiolucent and radiopaque lesions with wispy septa which result in resorption and displacement of the teeth involved. The accuracy of the diagnosis of OF can be enforced by a combination of clinical, radiographic and HPA examinations, so that the treatment given to patients is according to the procedure.

Keywords: *Ossifying fibroma, benign tumor, odontogenic tumor, CBCT 3D*

Cite this article: Romdlon MA, Pramanik F, Mauludin A. *Radiographic appearance of ossifying fibroma in the left mandible: a case report.* Jurnal Radiologi Dentomaksilofasial Indonesia 2023;7(2):83-8. <https://doi.org/10.32793/jrdi.v7i2.1056>



This work is licensed under a [Creative Commons Attribution 4.0](https://creativecommons.org/licenses/by-nc-nd/4.0/) which permits use, distribution and reproduction, provided that the original work is properly cited, the use is non-commercial and no modifications or adaptations are made.

INTRODUCTION

Ossifying Fibroma (OF) is a benign neoplasm originating from hard tissue, especially bones. OF is a true neoplasm with significant growth potential. OF is a benign neoplasm that can occur in any facial bone and has the potential for overgrowth, bone destruction, and recurrence. One of the characteristics of this disease is slow disease progression, painless. Another variant of OF is Juvenile OF which is an aggressive variant with rapid development that often attacks children aged less than 15 years.¹⁻³ These benign tumors occur more frequently in the mandible than the maxilla.

Grewal *et al.* in their case report stated that OF is very rare in the maxilla. The incidence of OF as much as 62% to 89% of all cases found are all in the mandible. Cases that occur in the mandible, as much as 77% occur in the premolars, while 75 to 89% occur in the molars.⁴ Usually cases of OF are diagnosed in the third to fourth decade, with a female predilection. The prevalence is more in the white race.⁵⁻⁸

The diagnosis of OF can be established based on clinical, radiographic and histopathological

examination. Radiographic examinations can be performed in 2D and 3D forms. 2D radiography, for example panoramic, is generally only used for initial screening. 3D radiography or Cone-beam Computed Tomography (CBCT) can provide information in the form of a detailed picture of the boundaries and extent of the lesion. This article aims to discuss in more depth the radiographic appearance of ossifying fibroma on CBCT radiography.

CASE REPORT

A 31-year-old man was referred to the Oral Surgery Department of the Al Ihsan Regional General Hospital, Bandung. The patient came with complaints of swelling near the back of the tongue. The patient feels no pain. On extra-oral clinical examination, there was no extra-oral swelling. Examination of the lymphnode was also not palpable. On the intra oral examination, there was visible loss of teeth 34 and 35. Swelling was seen in area mandibular sinistra, towards the lingual, with

¹Dentomaxillofacial Radiology Residency Program, Faculty of Dentistry, Universitas Padjadjaran, Bandung, Indonesia 40132

²Department of Dentomaxillofacial Radiology, Dental Education Study Program, Faculty of Medicine, Universitas Jenderal Soedirman, Banyumas, Indonesia 53122

³Department of Dentomaxillofacial Radiology, Faculty of Dentistry, Universitas Padjadjaran, Bandung, Indonesia 40132

⁴Al Ihsan Regional General Hospital, Bandung, Indonesia 40115

*Correspondence to:
Mahindra Awwaludin Romdlon
✉ mahindra.ar@unsoed.ac.id

Received on: July 2023
Revised on: August 2023
Accepted on: August 2023

swelling that was slightly hard when being pressed (Figure 1). The patient did not realize when the swelling started to grow in size, but had been feeling uncomfortable for the last 2 months. The color of the mucosa in the swelling area is not significantly different from the surrounding area. The patient had no other medical history, allergies were also denied.

Panoramic radiography discovered a left mandibular lesion with an anterior border on tooth 33 and a posterior border on tooth 38 (Figure 2). The superior border exceeds the height of tooth 33, the inferior border approaches the inferior cortical border of the mandible. Unilocular lesion, well defined. The internal structure of the lesion is a mixed appearance (radiopaque and radiolucent) accompanied by false septa, in some parts showing bone thickening or calcification. The lesion resulted in teeth 36 and 37 being displaced superiorly and root resorption. The lesions also result in loss of the

cortical boundary of the roof of the mandibular canal. Patients are referred to undergo a CBCT radiography to get a more detailed picture of the lesion. Based on the CBCT multiplanar (MPR) view as shown in Figure 3, it can be seen that the location of the lesion is in the left mandibular area.

Based on the coronal, sagittal and axial sections we analyzed the location, shape, size, symmetry, internal structure of the lesion, the edges of the lesion and the effect on the surrounding tissues. It can be seen that the lesion is a mixed lesion between radiopaque and radiolucent. The lesion appeared to compress the mandibular canal and resulted in a thinning of the inferior mandibular border and also resulted in destruction of the buccal and lingual cortical bone (Figure 4). There were also several wispy trabeculae in the left mandible from distal to tooth 32 to superior to the left mandible with an average internal density of lesions showing fluid/fatty tissue lesions

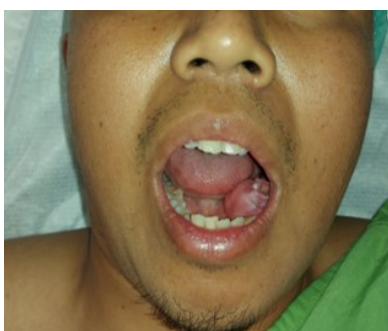

Figure 1. Clinical condition of the patient, showing swelling in the area of the posterior teeth close to the tongue

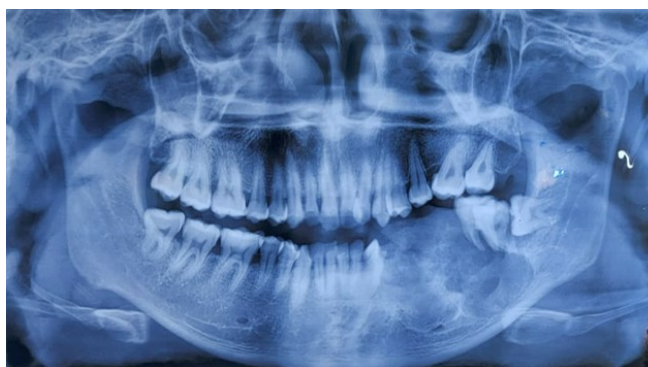

Figure 2. Panoramic radiograph showing a mixed radiolucent-radiopaque lesion in the posterior area of the mandibular body

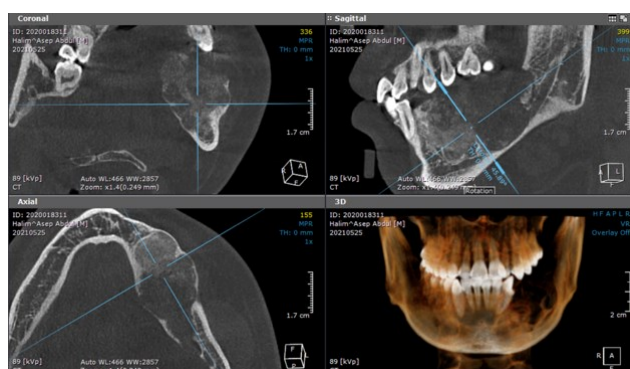


Figure 3. CBCT multiplanar view

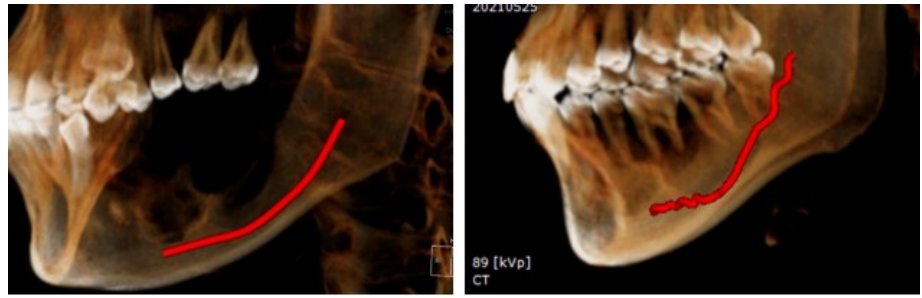

Figure 4. 3D CBCT view showing the relationship of the lesion to the mandibular canal

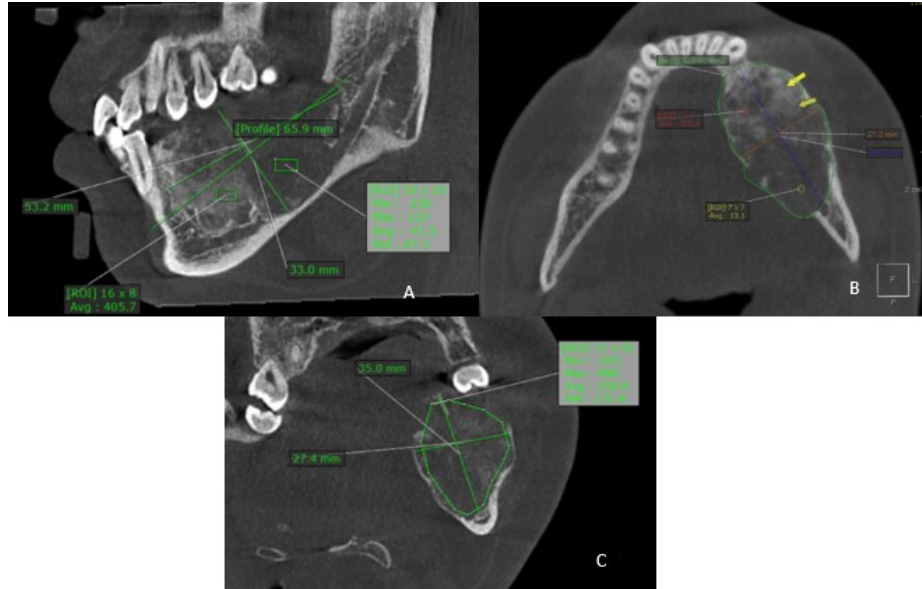


Figure 5. CBCT radiographs, (A) Sagittal section shows a mixed radiopaque radiolucent lesion in the mandibular body area of teeth 33-38, (B) Axial view shows buccal and lingual expansion of the lesion, (C) Coronal section showing a lesion expanding supero-inferiorly involving the mandibular canal

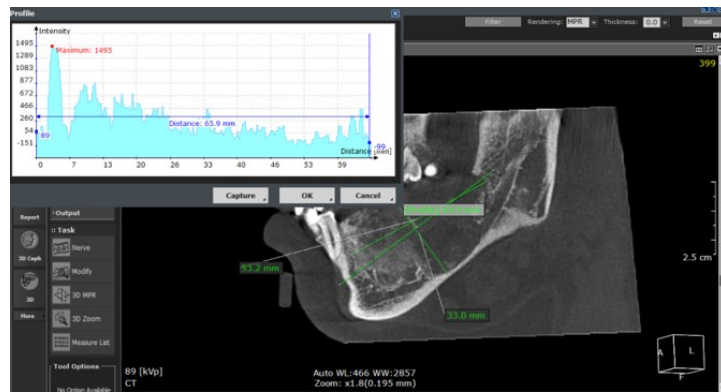


Figure 6. Density measurements through profiles showing differences in density within the lesion and the lesion boundaries

accompanied by hard tissue. The lesions are oval and unilocular.

In this case report, we also performed an analysis of lesion density through Region of Interest (ROI) and profile density measurements. Based on ROI measurements, we found that within these lesions there were differences in density indicating a mixed lesion (radiopaque-radiolucent) with a mean density of ± 547.5 Grayscale on the inferior side and ± 33.8 Grayscale on the superior side

(Figure 5A, 5B, 5C). We also measure density by measuring profiles. The density graph of a line drawn 8.00 mm across from the mandibular bone to the lesion shows a distinct grayscale distribution with a density peak in the middle. This suggests that there is a boundary separating the mandibular bone and the radiolucent lesion. Density graph of a line drawn 8.3 mm across from a radiolucent lesion to a radiopaque lesion (Figure 6) showing the different grayscale distributions. This shows the difference

between radiopaque and radiolucent lesions. The treatment carried out was to perform a segmental resection followed by the installation of a mandibular reconstruction plate to fix and restore mandibular function as seen in Figure 7.

The mandibular section taken was then subjected to histopathological examination, and the results of microscopic examination of the left mandibular preparation were covered by stratified squamous epithelium, the core within normal limits. Subepithelial visible fibrocollagen connective tissue stroma covered with lymphocyte inflammatory cells. Between the fibrocytic cells that grow hyperplastic, the nucleus is within normal limits. Some parts appear to be calcified with some osteosis, the nucleus is within normal limits. dilatation and dams of blood vessels were seen and no malignancy was seen.

DISCUSSION

In 1992, WHO issued the terminology of cemento-ossifying fibroma and in 2005 it was simplified to become Ossifying fibroma. In 2017, Ossifying fibroma was classified as benign mesenchymal odontogenic tumors.^{6,9} OF clinically can be seen at all ages, both young and adults. This disease is often found in an asymptomatic condition, sometimes accompanied by facial asymmetry, depending on the pattern, number and material of calcification of the lesion. In some cases, teeth were found to move. In young patients, rapid growth can result in destruction and deformity of the involved jawbone. This disease can affect the mandible (most commonly), maxilla, facial bones, periorbital, frontal, ethmoid, sphenoid, and temporal bones are also relatively common sites of this tumor.^{7,10} Theoretically, the OF radiographs

occurred in the mandible, involving the affected area from the premolars to the mandibular molars and canalis.⁷ The clinical picture was theoretically the same as the case we reported. OF development in the maxilla usually occurs in the fossa canina and the zygomatic arch.

The causes and pathophysiology of OF are still unclear, but several theories suggest that the etiology of OF is odontogenic, developmental and traumatic and related to the periodontal ligament because it produces cementum and osteoid. OF can develop from multipotential mesenchymal cells originating from the periodontal ligament which are capable of forming bone and cementum.¹¹ Several theories state that the extraction performed or periodontitis provides a stimulus for the formation of OF which is associated with bone maturation disorders that are congenital in origin.¹²

Radiographically, the appearance of an ossifying fibroma may differ depending on the amount of mineralized tissue in the tumor. Ossifying fibroma lesions are categorized according to four radiographic criteria, namely ground glass appearance, sclerotic change, mixed type and cystic radiolucency. The initial lesion is radiologically lytic but with time matrix mineralization increases, producing a mixed lytic and sclerotic appearance, usually a "lytic rim" surrounding the lesion.¹³ OF often appears as a well-circumscribed, unilocular lesion with a consistent number of radiopaque foci within lesion. As a result, radiographic images are often seen in the form of mixed radiopaque and radiolucent.¹² The boundaries of the lesion are generally well defined. A radiolucent line appears which shows a fibrous capsule which is bordered by the surrounding bone. The unilocular lesion with internal structure also exhibits a mixture of radiolucency and radio-opacity which exhibits abundant and amorphous calcification and lacks an intrinsic pattern. In some cases, abnormal trabecular bone, wispy (similar to cotton) or

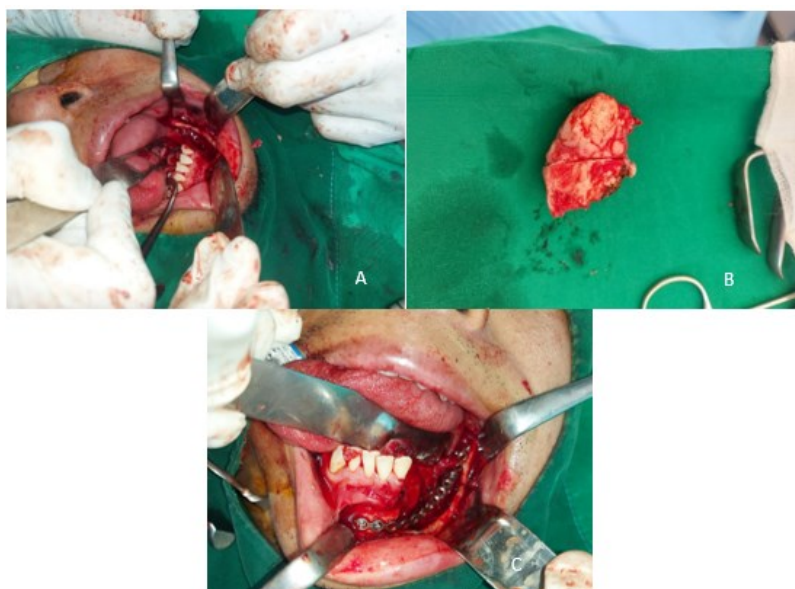


Figure 7. Surgical treatment, (A) Excision process under general anesthesia, (B) Excision results, and (C) Plate installation

flocculent (heavy snowflakes) is found, which is similar to fibrous dysplasia.¹⁰

OF can be distinguished from bone dysplasia by the habit of the tumor, which reflects the growth of the lesion which appears to be more concentric on the inside and causes expansion outward in all directions, thereby resulting in tooth displacement, loss of lamina dura, resorption of the mandibular root and canal and expansion of the cortical bone plates. Generally, cortical plates that experience expansion become thinner and remain intact. OF in the maxilla can fill the entire maxillary sinus resulting in expansion of the sinus border. In small lesions, patients are asymptomatic and detected incidentally on radiographs.^{10,14,15}

In the case report by Jih *et al.* who reported 4 cases of ossifying fibroma, it was found that all four cases had clear boundaries and little expansion. In 2 cases the expansion was buccal, while 1 case displayed lingual expansion with thinning of the cortical bone (this condition is the same as the case we report which was lingual expansion). In the latter case, no swelling was observed. Inferior shift of the mandibular canal was observed in 3 cases (this condition was also experienced by our patient) and 1 case only showed tooth displacement (the same was the case in the case we reported).⁷

Histopathological examination of OF in this case report showed a left mandibular preparation covered with stratified squamous epithelium, the core within normal limits. Fibrocollagen connective tissue stroma with lymphocyte inflammatory cells is seen. There are also fibrocytic cells that grow in hyperplastic manner. In some parts it appears to experience calcification accompanied by osteocytes. There did not appear to be any malignancy. This is in accordance with case reports that have been published by other authors before.^{11,13,16}

The differential diagnosis of OF is mixed radiolucency radiopaque lesions. Sometimes difficult to distinguish from fibrous dysplasia (FD). The boundaries of the OF are usually better defined, and these lesions sometimes have soft tissue covered with a capsule and cortex, whereas the FD is usually fused with the surrounding bone. The internal structure of FD lesions in the maxilla may be more homogeneous and show less variation. In cases of fibrous dysplasia, it is often accompanied by pain. FD results in minimal alteration of bone morphology and very rarely resorbs teeth. Both types of lesions can result in tooth displacement. In this case we see the capsule of lesion, root resorption and heterogeneity composition of the lesion (radiopaque and radiolucent), so that FD can be eliminated from definite diagnosis.^{8,11,15}

Another differential diagnosis is periapical osseous dysplasia (POD), especially in single and large lesion of POD. POD cases often occur in a multifocal manner, while OF does not. In POD it is common to see enlarged sclerotic edges of the lesion suggesting that the slow development of POD and its expansion does not result in massive bone destruction. The epicentrum of the POD is

apical to the tooth in the alveolar bone. In this case we can see the lesion have a very large size which make destruction of the cortical plate buccal and lingual but in POD not found that thing, so we can be eliminated POD from definite diagnosis.^{7,10}

Another differential diagnosis is Cementoblastoma which is a benign neoplasm originating from cementum that has the ability to proliferate. Clinically found swelling and pain in the patient. The manifestation of this tumor is round and extends to the cementum of the root of the tooth. The edge of cementoblastoma appears radiolucent. Cementoblastoma can result in root resorption. In this case we can see root resorption, but this lesion not correlated with cementum of the teeth. So that cementoblastoma can be ruled out from a definite diagnosis and can only be used as a differential diagnosis.^{4,7}

Appropriate treatment can be carried out if the diagnosis process is carried out properly. OF has the characteristics of well-defined and separated from the bone even though the lesion reaches a very large size, so that complete excision and resection must be carried out. OF lesions are poorly vascularized and circumscribed, so the risk of removing the lesion from the surrounding bone is relatively low. In this case a segmental resection was performed from the left parasymphysis to the left mandibular angle. The next treatment is the installation of a mandibular reconstruction plate (bridging plate) which aims to restore normal mandibular function after resection and replaces the missing portion of the mandibular bone for normal masticatory function and normal outer contour of the jaw.^{8,10} The prognosis of this disease is good. To date there are no reliable prognostic or predictive biomarkers to define Ossifying fibroma. Treatment of excision of the entire lesion rarely results in recurrence. Until now, the transformation of the lesion to become malignant is uncertain.¹³

CONCLUSION

Ossifying fibroma lesions are benign tumor lesions originating from bone hard tissue. Making the right diagnosis really supports the treatment that will be carried out to the patient. Investigations that can be carried out are panoramic radiography, CBCT and histopathology. This lesion has a mixed radiolucent-radiopaque radiographic appearance. These lesions have the characteristics of benign tumors, encapsulated and can expand in all directions. CBCT radiographic examination is very helpful in planning treatment because CBCT provides a detailed picture of the lesion. Segmental resection treatment has been successfully performed in this patient.

ACKNOWLEDGMENTS

None.

FOOTNOTES

All authors have no potential conflict of interest to declare for this article. Informed consent was obtained from the patient for being included in this case report.

REFERENCES

1. Brad WN, Douglas DD, Carl MA, Angela CC. Oral and Maxillofacial Pathology. 4th ed. Missouri: Elsevier; 2016. p.602.
2. Joseph AR, James JS, Richard CKJ. Oral Pathology: Clinical Pathologic Correlations. Seventh Edition. Missouri: Elsevier; 2017. p.293.
3. Dios PD, Scully C, de Almeida OP, Bagán Jv, Taylor AM. Oral Medicine and Pathology and Pathology at a Glance. Second Edition. John Wiley & Sons, Ltd; 2016. p.119.
4. Grewal M, Gautam S, Tanwar R, Saini N. Cemento-ossifying fibroma of maxilla: An unusual case report. Journal of Dental Research and Review. 2020;7(4):206-9.
5. Glick M. Burket's Oral Medicine 12th edition. 12th ed. Connecticut: People's Medical Publishing House; 2015. p.162.
6. Kharsan V, Madan RS, Rathod P, Balani A, Tiwari S, Sharma S. Large ossifying fibroma of jaw bone: A rare case report. Pan African Medical Journal. 2018;30:306.
7. Jih MK, Kim JS. Three types of ossifying fibroma: a report of 4 cases with an analysis of CBCT features. Imaging Sci Dent. 2020;50(1):65-71.
8. Patait M, Choudhary V, Mathew A, Mangrolia R, Ahire M. Cemento-ossifying fibroma: Case report. International Journal of Applied Dental Sciences. 2020;6(4):215-8.
9. Wright JM, Vered M. Update from the 4th Edition of the World Health Organization Classification of Head and Neck Tumours: Odontogenic and Maxillofacial Bone Tumors. Head Neck Pathol. 2017;11(1):68-77.
10. White SC, Pharoah MJ. Oral Radiology Principles and Interpretation. 7th ed. Missouri: Elsevier; 2014. p.394.
11. Swami AN, Kale LM, Mishra SS, Choudhary SH. Central ossifying fibroma of mandible: A case report and review of literature. Journal of Indian Academy of Oral Medicine and Radiology. 2015;27(1):131-5.
12. Haq EU, Minhas S, Asad R, Kashif M. An unusual case of ossifying fibroma in the anterior maxilla: a case report. J Dent Health Oral Disord Ther. 2018;9(5):382-5.
13. Slootweg PJ, Baumhoer D. Cancers of the Jaws; Pathology and Genetics. In: Reference Module in Biomedical Sciences. Elsevier; 2017.
14. Prabhu SR. Handbook of Oral Pathology and Oral Medicine. Oxford: John Wiley & Sons Ltd; 2022. p.185.
15. Poonja P, Sattur A, Burde K, Nandimath K, Hallikeri K. Ossifying fibroma of mandible-a concise radiographic exploration. Gulhane Medical Journal. 2019;61(3):132-4.
16. Lubis RT, Rahman FUA, Nurrahim MA, Epsilawati L, Oli'i EM. Ossifying Fibroma pada mandibula pasien anak. Jurnal Radiologi Dentomaksilofasial Indonesia (JRDI). 2020;31;4 (2):21-5.