



Characteristics of root resorption in mandibular ameloblastoma using digital radiography

Trisutrisno Papatungan^{1*} , Barunawaty Yunus² 

ABSTRACT

Objectives: This study aims to provide insights into the characteristics of root resorption associated with ameloblastoma as detected on digital radiography.

Review: Root resorption is a pathological process marked by the progressive loss of the root structure, which may result from bacterial infection, traumatic injury, or chemical irritation. Ameloblastoma frequently exhibits distinctive patterns of root resorption, often presenting as blunted or sharply demarcated margins on digital radiographs.

Conclusion: Ameloblastoma is known for its high recurrence rate, necessitating comprehensive surgical excision to minimize the likelihood of recurrence. Surgical management often includes the removal of the affected teeth along with the tumor. These treatment decisions are generally guided by histopathological confirmation through incisional biopsy, as several lesions can mimic ameloblastoma despite characteristic radiographic findings such as root resorption.

Keywords: Ameloblastoma, digital radiography, root resorption

Cite this article: Papatungan T, Yunus B. Characteristics of root resorption in mandibular ameloblastoma using digital radiography. *Jurnal Radiologi Dentomaksilofasial Indonesia* 2026;10(1):280-289.
<https://doi.org/10.32793/jrdi.v10i1.1500>

INTRODUCTION

Laboratory examinations and radiographs are often crucial in establishing a diagnosis. Radiographic examination is an important step and a valuable tool in detecting bone lesions and pathological processes that are not visible through physical examination.¹ Root resorption in permanent teeth may result from trauma, periapical inflammation, orthodontic tooth movement, impacted teeth, or neoplastic processes, and it can be classified as either internal or external resorption. Pathological root resorption, defined as the progressive loss of the tooth root structure, is most commonly associated with bacterial infection, traumatic injury, or chemical irritation. In cases of ameloblastoma, root resorption demonstrates distinctive features, often appearing as blunted or sharply demarcated margins on digital radiographs. In some instances, resorption may even extend to involve the crown. External root resorption is characterized by the loss of dentin and cementum due to the activity of osteoclastic cells. Radiographically, this condition is frequently observed in teeth adjacent to odontogenic cysts and benign tumors of the jaws, including radicular cysts, dentigerous cysts, odontogenic keratocysts (OKCs), and ameloblastomas.^{2, 3, 4}

Ameloblastoma is a benign odontogenic neoplasm arising from remnants of the dental

lamina epithelium.⁵ Due to its asymptomatic nature, patients often seek medical treatment only when facial deformities become apparent.⁶ The management of ameloblastoma remains controversial, with two primary surgical approaches: conservative and radical. Conservative treatment typically involves enucleation, curettage, or cryosurgery, whereas radical treatment entails surgical resection with clear bone margins of 1–2 cm beyond the radiographic boundary. This margin is recommended because tumor infiltration may extend beyond radiologically visible limits. Reported recurrence rates are substantially higher in patients treated conservatively (up to 90%) compared to those treated with radical resection (approximately 5%).⁷

Radiographic detection of root resorption is not an easy task, and one of the main reasons is that in two-dimensional (2D) radiographs, such as intraoral or panoramic radiographs, the projection of three-dimensional (3D) objects into a 2D image results in the loss of information that may be needed to detect resorptive lesions. This fact also explains why cone beam computed tomography (CBCT) imaging is superior when detecting external root resorption. However, the potential negative effects posed by the much higher radiation doses compared to 2D radiographs outweigh the benefits of CBCT imaging.⁸

¹Department of Oral and Maxillofacial Radiology, Faculty of Dentistry, Hasanuddin University, Makassar, Indonesia

²Department of Oral and Maxillofacial Radiology, Faculty of Dentistry, Hasanuddin University, Makassar, Indonesia

*Correspondence to:
Trisutrisno Papatungan
✉ Dentris665@gmail.com

Received on: January 2026
Revised on: April 2026
Accepted on: April 2026



This work is licensed under a Creative Commons Attribution 4.0 which permits use, distribution and reproduction, provided that the original work is properly cited, the use is non-commercial and no modifications or adaptations are made.

Based on the aforementioned considerations, this review aims to comprehensively evaluate the radiographic characteristics of root resorption associated with mandibular ameloblastoma, with particular emphasis on its appearance in digital radiography and its role in differentiating ameloblastoma from other odontogenic and non-odontogenic lesions.

REVIEW

A comprehensive literature search was conducted to identify relevant studies evaluating radiographic features of root resorption in ameloblastoma. The search was performed using electronic databases, including PubMed/MEDLINE, Scopus (Elsevier), and Google Scholar, to ensure broad coverage of peer-reviewed literature in dentomaxillofacial radiology. The search strategy combined Medical Subject Headings (MeSH) and free-text terms, including “ameloblastoma,” “root resorption,” “Knife-edge root resorption,” “digital radiography,” “panoramic radiography,” and “cone beam computed tomography (CBCT),” with the application of Boolean operators (AND, OR) to refine the results.

The initial search yielded 78 articles, of which 16 duplicates were removed, resulting in 62 articles for title and abstract screening. Following this stage, 49 articles were excluded due to a lack of relevance to radiographic evaluation or the absence of a specific discussion on root resorption in ameloblastoma. Thirteen full-text articles were subsequently assessed for eligibility, and based on predefined inclusion and exclusion criteria, five studies were included in the final qualitative synthesis, corresponding to the studies summarized in Table 1 of this review.

Ameloblastoma is a benign odontogenic tumor arising in the maxilla and mandible from epithelial cell remnants and dental tissue.^{9–14} According to the 2017 World Health Organization (WHO) classification of head and neck tumors, ameloblastoma is categorized into three subtypes: unicystic, extraosseous/peripheral, and the most common form, intraosseous ameloblastoma.^{15–20} Clinically, ameloblastoma is generally a painless, slow-growing neoplasm that is locally aggressive. It often leads to cortical bone expansion, perforation of the lingual or buccal cortical plates, and occasionally soft tissue infiltration. The peak incidence occurs during the third and fourth decades of life, although cases have been reported across all age groups, with no significant gender predilection (male-to-female ratio approximately 1:1). The relative frequency of mandibular versus maxillary involvement has been reported to range from 80:20 to as high as 99:1. The mandible is the most frequently affected site, with Reichart et al. reporting a prevalence of 87.2% in the mandible compared to 8.5% in the maxilla.^{21,22,23,24} Within the mandible, the molar–ramus region represents the

most common location. Overall, ameloblastoma demonstrates no gender predilection, with equal occurrence in males and females, and is most frequently encountered in the posterior mandible, with a mandible-to-maxilla ratio of approximately 5:1.²⁵

Ameloblastoma is the most common odontogenic tumor of the jaws, accounting for approximately 10%–14% of all odontogenic tumors.^{26,27} Radiographically, it typically presents as a unilocular or multilocular radiolucent lesion, often associated with impacted teeth, tooth displacement, root resorption, cortical bone expansion, and cortical perforation. The presence of internal septa frequently produces a characteristic “soap bubble” or “honeycomb” appearance.²⁸ Management strategies for ameloblastoma include enucleation, curettage, or surgical excision, depending on the lesion’s size, location, and histological subtype. Reported recurrence rates range from 17.7% following resection to 34.7% with conservative approaches. Radical resection with margins extending into clinically uninvolved bone is generally recommended to reduce recurrence. Treatment is also subtype-dependent: solid/multicystic ameloblastomas are usually treated with wide excision, whereas peripheral/extraosseous lesions can be managed conservatively.^{23,29} Comparative studies by Hendra et al. and others indicate that radical treatment is associated with lower recurrence rates than conservative management.^{30–32} In unicystic ameloblastoma, conservative therapy is more frequently associated with delayed but higher recurrence compared to radical approaches.³³ Histologically, ameloblastoma is characterized by islands of odontogenic epithelium with loosely arranged stellate reticulum-like cells forming microcystic structures, surrounded by columnar basal cells exhibiting reversed nuclear polarity and supranuclear vacuolization.³⁴

Clinically, ameloblastoma often manifests as swelling, particularly in the mandibular symphysis or posterior region, depending on the lesion site. With the exception of the peripheral type, ameloblastoma arises intraosseously and is frequently detected incidentally on routine radiographs, such as panoramic radiographs or intraoral films. Radiographically, it appears as a lytic lesion with scalloped borders, root resorption, and frequently associated impacted molar teeth, especially in the unicystic variant. Several studies report variable frequencies of impacted teeth ranging from 0% to 26%, whereas Hendra et al. documented a notably higher prevalence of 40.5%. Similarly, root resorption has been reported at rates up to 87.9%, considerably higher than in other series.^{35,36} A definitive diagnosis of ameloblastoma cannot be established solely on clinical or radiographic findings; histopathological confirmation via biopsy remains the gold standard.³⁷

Table 1. Summary of studies on root resorption patterns in mandibular ameloblastoma using radiographic imaging

Author (Year)	Title	Conclusion	Identified Radiographic Features / Imaging Methods	Design of Study
Martins GG et al. (2019) ³⁸	The mechanism: How dental resorptions occur in ameloblastoma	Root resorption in ameloblastoma is caused by tumor–tooth interaction mediated by cytokines and growth factors. The resorption is typically sharp, straight, and pointed, often described as knife-edge resorption, and is considered a highly suggestive feature of ameloblastoma compared to inflammatory cysts.	<ul style="list-style-type: none"> •Panoramic radiography •Histopathological correlation • Typical knife-edge root resorption 	Narrative/ Mechanistic Review
More C. (2012). ³⁹	Radiographic analysis of ameloblastoma: A Restospective study	Ameloblastoma frequently shows multilocular radiolucency with adjacent root resorption presenting sharp, tapered or knife-edge pattern, helping to differentiate it from dentigerous and radicular cysts.	<ul style="list-style-type: none"> •Panoramic radiograph •Periapical radiograph • Knife-edge & blunt root resorption 	Case series/ Restospective study
Jehan R. et al. (2022). ⁴⁰	Root resorption in ameloblastoma: A radiographic analysis of 35 cases	Root resorption was present in the majority of mandibular meloblastoma cases. The dominant pattern observed was knife-edge and tapering resorption, reinforcing it as an important diagnostic marker in conventional and digital radiography.	<ul style="list-style-type: none"> •Digital panoramic radiograph •Root resorption evaluation (sharp / knife-edge) 	Retrospective radiographic analysis
Rashi Mandlik,et al. (2024). ⁴¹	Unveiling Radiographic Features and Radio patholical Correlations of Ameloblastoma: A Retrospective Study	The outcomes of this study help to comprehend the radiographic features and histological patterns of ameloblastoma. In the current study, statistically significant correlations were found between radiographic patterns and histological type. There is limited literature on such a relationship. By evaluating this, the study sheds light on the clinical aspects and behavior of this neoplasm.	<ul style="list-style-type: none"> •Panoramic radiography •CBCT in some cases •Root resorption & tooth displacement/ In the present study, 68.9% root resorption was seen; similarly, 78.57% root resorption was found in the study of More et al. Knife edge root resorption was the most common pattern observed in the current study [46.7%]), which is favored by Martins et al. 	Retrospective Study
Garg, M. et.all. (2017). ⁴²	Clinico- radiological and Histopathological Correlation of 56 Cases of Ameloblastoma:	It must be stressed that our knowledge of biological behavior of ameloblastoma is still insufficient for drawing a definite conclusion. Our	Unilocular radiolucency involving body, angle, and ramus on right side of mandible.	Retrospectively reviewed and analyzed

Author (Year)	Title	Conclusion	Identified Radiographic Features / Imaging Methods	Design of Study
A	10-Year Retrospective Analysis in North Indian Population	study was done in small sample and further studies are required to confirm my observations. Treatment strategies can be better decided.	Downward displacement of impacted mandibular third molar. Knife-edge root resorption. CBCT image showing an osteolytic lesion causing bone destruction and cortical perforation on right side mandibular region.	

DISCUSSION

Root resorption is a multifactorial condition characterized by the progressive destruction and eventual loss of dentin and cementum.⁴³ It may be classified as either internal or external resorption. Root resorption represents a physiological or pathological process in which mineralized tissues such as dentin, cementum, and alveolar bone are progressively lost.⁴⁴ Different types of resorption may affect the teeth, each with distinct etiologies and pathogenetic mechanisms. A widely recognized concept describing the pathogenesis of resorption is the so-called "Resorption Triad" (Figure 1), which requires three essential components: (a) damage to the natural protective barriers, (b) the presence of

continuous stimulating factors, and (c) a viable blood supply to clastic cells. The occurrence of all three conditions is necessary for resorption to take place. Natural protective barriers include the periodontal ligament (PDL) and cementum externally, as well as odontoblasts and predentin internally. These barriers serve as defense mechanisms that prevent clastic cells from adhering to or penetrating the unmineralized matrix of cementum and dentin. Stimulating factors that trigger resorption may include bacterial infection within the root canal system, necrosis of the PDL following traumatic injury, the presence of impacted adjacent teeth, or the influence of neighboring cysts or tumors.^{45, 46}

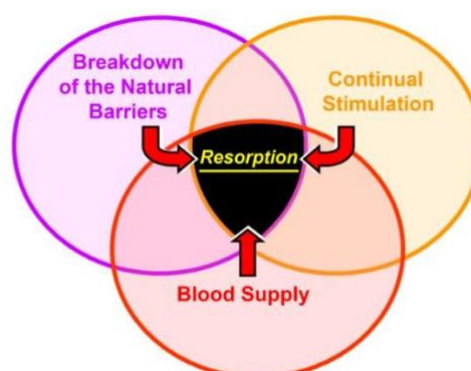


Figure 1. The Resorption Triad" depicts the three common prerequisites for resorption to occur.

Root resorption is a characteristic radiographic feature of ameloblastoma and is often considered pathognomonic, as it distinguishes ameloblastoma from other jaw lesions such as simple bone cysts, keratocystic odontogenic tumors, and nasopalatine duct cysts, which typically do not induce root resorption in the involved teeth. Although this feature has high diagnostic value in differentiating ameloblastoma from other lesions, histopathological confirmation remains essential before establishing a definitive diagnosis and formulating an appropriate treatment plan. Notably, in three out of four of the most frequently encountered radiolucent or hypodense jaw cysts

associated with tooth roots, the affected teeth usually remain intact without evidence of root resorption.³⁸ These lesions include Simple Bone Cysts, Keratocystic Odontogenic Tumor, Nasopalatine Duct Cyst.

Simple Bone Cysts

Radiographically, simple bone cysts (Figure 2) are typically characterized by well-defined, continuous radiolucent borders that clearly delineate the lesion from the surrounding bone. The cystic margin often conforms to the contours of the adjacent tooth roots, without disruption of the lamina dura, periodontal ligament space, or root

structure. Importantly, the involved teeth remain vital and are not displaced, and no evidence of root resorption is observed. The absence of root resorption in simple bone cysts can be attributed to their slow rate of development and the lack of an epithelial lining or capsule. These lesions progressively resorb trabecular and cortical bone

without affecting the periodontal ligament or pulp. The protective cementum layer remains intact, preventing resorptive activity. Furthermore, the gradual growth of simple bone cysts does not generate significant pressure on the roots or surrounding cortical bone, thereby preserving tooth integrity.³⁸

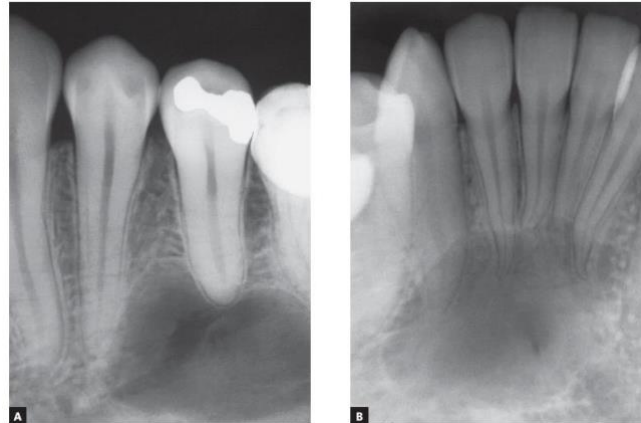


Figure 2. Intraoral Periapical View of Simple Bone Cyst: the cyst surrounds the tooth root, does not affect the lamina dura, periodontal space, or root integrity, and does not cause root resorption

Keratocystic Odontogenic Tumor

The keratocystic odontogenic cyst is typically asymptomatic and, during its growth, does not compress the neurovascular structures supplying the pulp. For several decades, this lesion was

considered a neoplasm and was widely referred to as the keratocystic odontogenic tumor. However, in the most recent World Health Organization (WHO) classification, it has been reclassified as an odontogenic neoplasm.

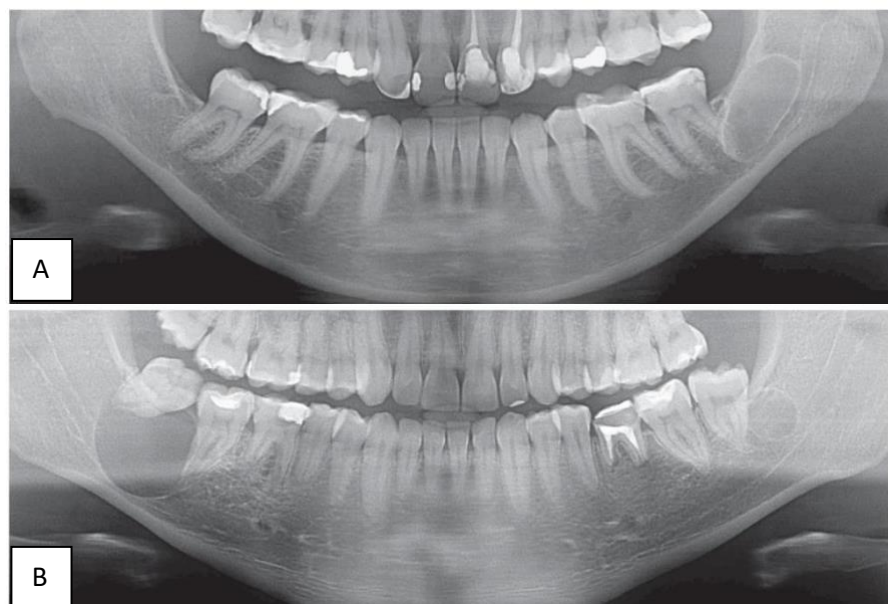


Figure 3. Panoramic View of Keratocystic Odontogenic Tumor Involving Mandibular Molar Teeth. In (A), no root resorption is visible despite the presence of a cyst. In (B), two keratocystic odontogenic tumors involving teeth are observed, but the cysts do not cause root resorption, aiding in the differential diagnosis of ameloblastoma

The absence of root resorption in keratocystic odontogenic cysts can be explained by their growth mechanism. These cysts expand through thin epithelial proliferation, typically only 5–10 cell layers thick. The keratin layer that fills the cystic lumen develops slowly and exerts minimal pressure on surrounding tissues such as the periodontal ligament. As a result, cementoblasts remain intact, preventing clastic cell activity on the root surface

that would otherwise lead to resorption. Moreover, keratocystic odontogenic cysts are usually free from inflammation, which is a key mediator of tooth and bone resorption. Although both ameloblastoma and odontogenic keratocysts present as radiolucent jaw lesions, their biological behavior differs. Keratocystic odontogenic cysts primarily grow through progressive epithelial proliferation at multiple foci, producing a characteristic wavy

border radiographically. However, in contrast to ameloblastomas, root resorption is uncommon and, when present, progresses slowly due to the absence of inflammatory mediators.^{38,47,48,49}

Nasopalatine Duct Cyst

The nasopalatine duct cyst is a non-odontogenic developmental cyst that arises from epithelial remnants of the nasopalatine duct within the incisive canal. Although its etiological triggers remain unclear, it is more frequently observed in

the maxilla. The absence of root resorption in nasopalatine duct cysts is primarily attributed to their slow growth rate. This gradual expansion provides sufficient time for adjacent central incisors to migrate distally, leading to root divergence and crown convergence without compromising root integrity. The protective role of the periodontal ligament and cementoblasts is preserved, thereby preventing clastic activity and root resorption in teeth adjacent to these cysts.^{38,44}

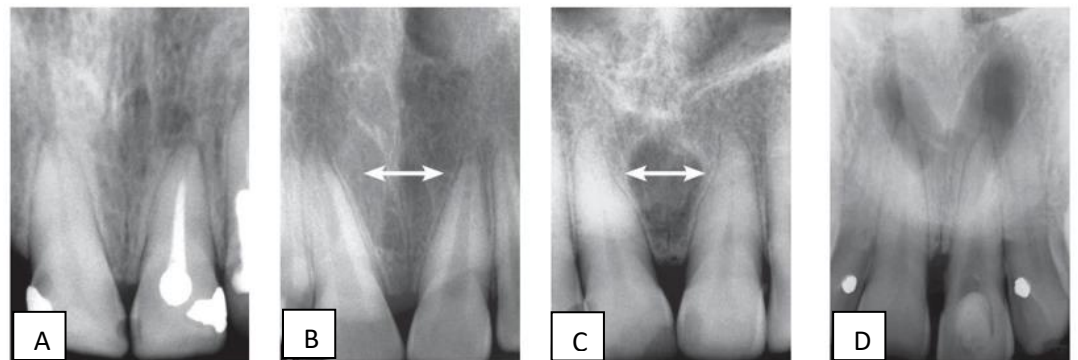


Figure 4. Nasopalatine Duct Cyst: Growth, as shown in images (A) and (D), with preserved roots, visible separate spacing on the roots between central incisors in images (B) and (C), and crown convergence. The cyst is always found in the anterior midline, between the maxillary central incisors. The lamina dura and periodontal space are not affected due to very slow growth, which prevents root resorption.

Small ameloblastomas may mimic periapical lesions, simple bone cysts, keratocystic odontogenic tumors (Figures 2–5), or, less commonly, nasopalatine duct cysts, as involvement of the anterior maxilla is rare. Despite their benign nature, ameloblastomas are aggressive odontogenic tumors due to their locally invasive behavior and high recurrence rates. Although often asymptomatic, they characteristically induce root resorption but rarely cause tooth displacement. Root resorption associated with ameloblastoma typically presents as a knife-edge pattern, forming an acute angle with the long axis of the tooth and contacting the

tumor tangentially. Struthers and Shear reported a high prevalence of root resorption (81%) in ameloblastoma cases.^{42,45} Christopher et al. found that 42% of ameloblastomas were unilocular and 58% multilocular on radiographs, with root resorption observed in 42% of cases.²⁵ Pereira-Castro-Lopes et al. described a case of a 20-year-old male with an extensive ameloblastoma in the right mandibular ramus causing marked root resorption.⁵¹ The mechanism of root resorption in ameloblastoma has been described in six sequential stages (Figure 6).³⁸

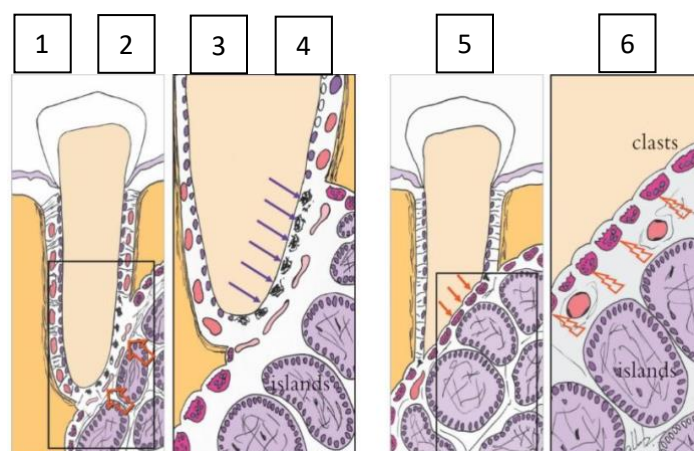


Figure 5. Stages 1 and 2, Stages 3 and 4, Stage 5, Stage 6

The first stage: Neoplastic cells compress blood vessels. The second stage is anoxia on cementoblasts. The third stage, Death of cementoblasts and root exposure, begins. The fourth stage: Exposure of the root surface attracts clasts. The fifth stage is root resorption with a knife-

edge. The sixth stage is stimulation by local neoplastic mediators IL1 and EGF.

To initiate the resorption process, osteoclasts must migrate, fuse, attach to the surface, acquire polarization, and form new membrane domains, then demineralize hydroxyapatite and destroy the

organic matrix. Immunological mechanisms play a crucial role in the initiation and continuation of pathological resorption.⁵² External pressure resorption occurs when persistent mechanical pressure is applied to the external surface of the tooth root, leading to progressive loss of mineralized tissues. The term pressure highlights the etiological role of mechanical force as a trigger

for resorption. In ameloblastoma, diagnosis is often based on radiographic findings. A hallmark feature is root resorption, typically presenting with a distinctive knife-edge configuration, where the resorbed surface forms an acute angle with the long axis of the tooth.^{10,38} In one study, this knife-edge resorption pattern was observed in approximately 70% of affected teeth.⁵³

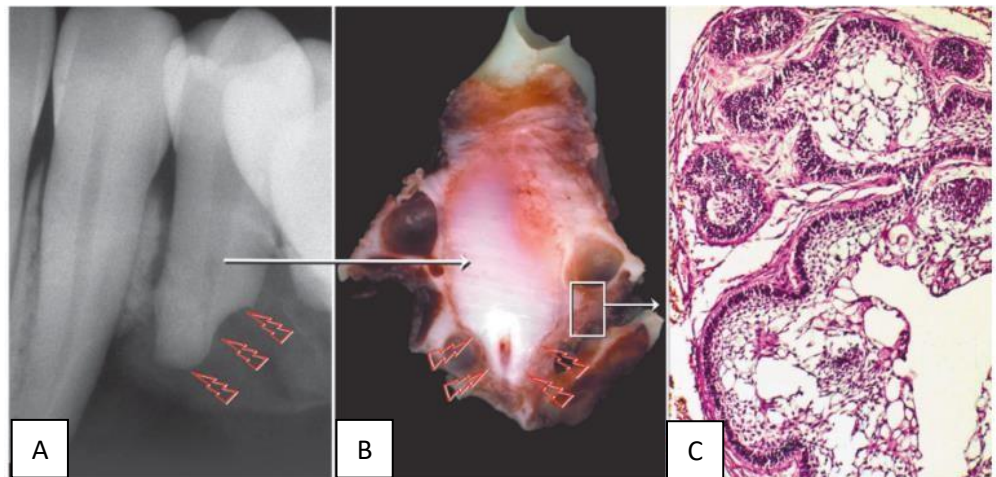


Figure 6. Root resorption in the form of a knife-edge (arrow) on the premolar caused by ameloblastoma (A). Macroscopic radiographic appearance of surgical specimen section (B), section for microscopic examination showing epithelial islands with cells resembling pre-ameloblasts and stellate reticulum of tooth germ, and release of resorption mediators (C)

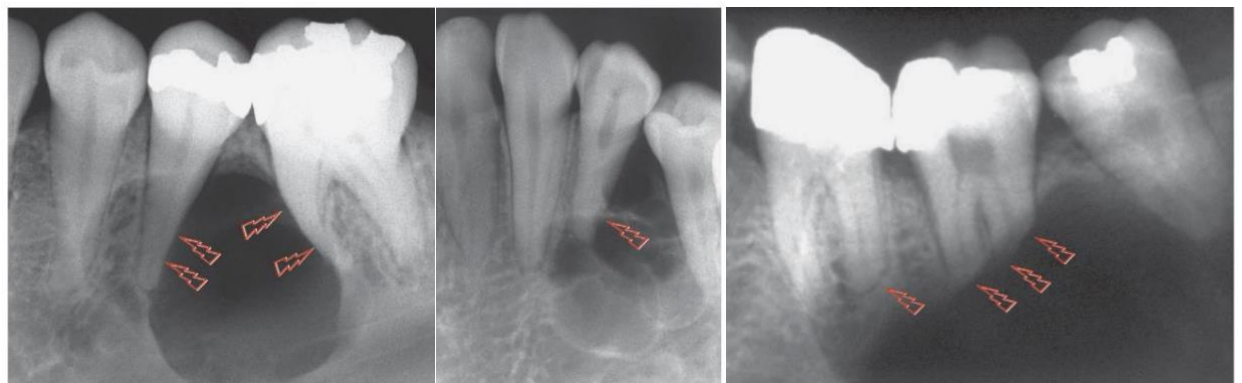


Figure 7. Newly initiated root resorption on the premolar associated with the early stage of ameloblastoma (arrow)

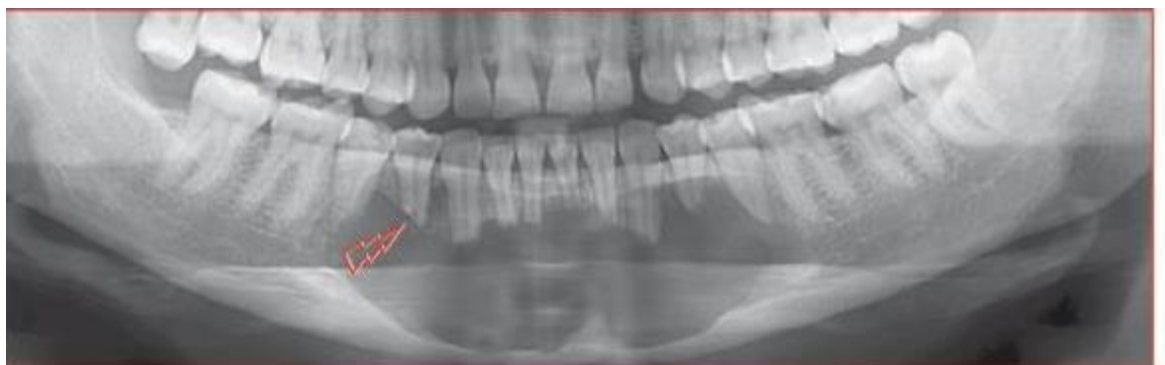

Figure 8. Knife-edge root resorption on the involved molar, which is a characteristic feature of solid or unilocular ameloblastoma (arrow)

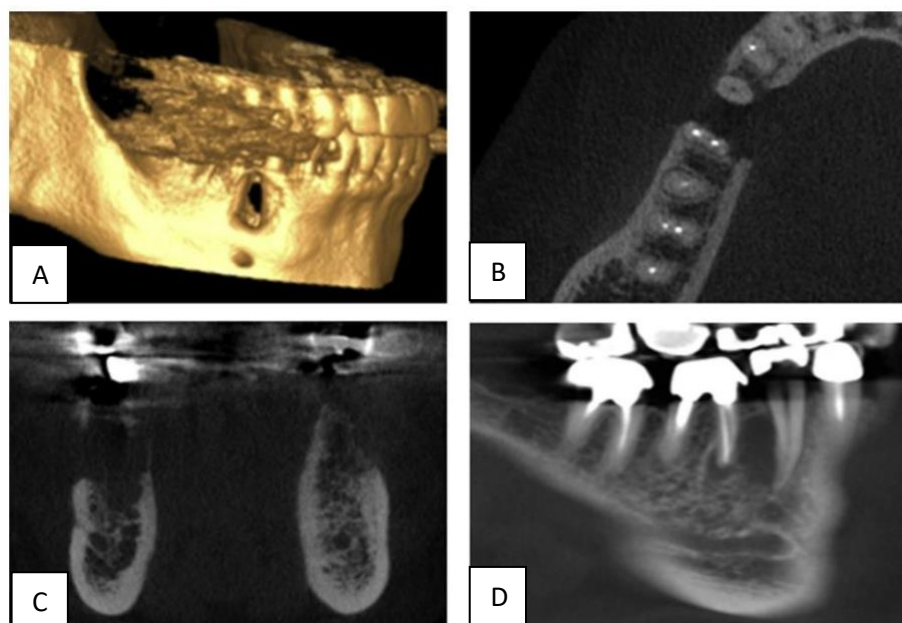


Figure 9. Knife-edge root resorption on the involved tooth, which is a characteristic feature of ameloblastoma (arrow), distinguishes it from other cysts with similar appearances in imaging studies. Incidental finding of mandibular lesion on three-dimensional CBCT scan (A), axial (B), coronal (C), corrected sagittal (D).⁵⁴

Since the late 1980s, radiographic digitalization has progressively replaced conventional film-based methods in routine dental practice.⁵⁵ The most common techniques for detecting external root resorption include conventional or digital intraoral radiography.⁵⁶ Both periapical and panoramic radiographs can provide valuable diagnostic information. Panoramic radiography offers an overview of the lesion and surrounding structures, while periapical radiography provides more detailed visualization of the lesion area.

Radiographic diagnosis of external root resorption can therefore be achieved with periapical radiography or, more recently, cone beam computed tomography (CBCT). Variations in reported frequencies of root resorption across different studies of the same lesion may, in part, reflect differences in the radiographic methods employed. CBCT enables three-dimensional visualization of tooth roots adjacent to pathological lesions, effectively eliminating the superimposition of structures commonly encountered in conventional radiographs. However, the significantly higher radiation dose of CBCT compared with two-dimensional techniques often outweighs its advantages. Despite advances in modern imaging modalities, panoramic radiography remains a valuable diagnostic tool. It provides useful information for estimating tumor invasion and root resorption, while maintaining relatively low radiation exposure compared with CBCT.^{2,8,10}

CONCLUSION

The detection of root resorption in ameloblastoma can be reliably achieved using digital radiography, where it typically appears as knife-edge resorption. This radiographic feature serves as a distinguishing characteristic of ameloblastoma (Figures 7–10), separating it from other jaw lesions. In contrast, simple bone cysts,

odontogenic keratocysts, and nasopalatine duct cysts do not induce root resorption in the involved teeth. This difference provides an important diagnostic clue when clinical findings and imaging features overlap with ameloblastoma. Despite the high diagnostic value of knife-edge resorption in differential diagnosis, histopathological confirmation remains essential. Microscopic examination should always be performed prior to establishing a definitive diagnosis and determining an appropriate treatment plan.

ACKNOWLEDGMENTS

-

FOOTNOTES

All authors have no potential conflict of interest to declare for this article.

REFERENCES

- Cardoso LB, Lopes IA, Ikuta CRS, Capelloza ALA. Study Between PanoramicRadiography and Cone Beam-Computed Tomography in the Diagnosis of Ameloblastoma, Odontogenic Keratocyst, and Dentigerous Cyst. *J Craniofac Surg.* 2020;31(6):1747–52.
- To KW, Shi AH, Teh LY, Lee AMH. External root resorption in common odontogenic cysts and ameloblastomas of the jaw: A retrospective radiographic study in an Asian population. *Oral Surg.* 2021;14(4):335–41.
- Liu Z, Liu J, Zhou Z, Zhang Q, Wu H, Zhai G, et al. Differential diagnosis of ameloblastoma and odontogenic keratocyst by machine learning of panoramic radiographs. *Int J Comput Assist Radiol Surg [Internet].* 2021;16(3):415–22. Available from: <https://doi.org/10.1007/s11548-021-02309-0>
- Lin S, Marvidou AM, Novak R, Moreinos D, Abbott PV, Rotstein I. Pathogenesis of non-infection related inflammatory root resorption in permanent teeth: A narrative review. *Int Endod J.* 2023;56(12):1432–45.
- Feranasari AAIA, Epsilawati L, Pramanik F. Laporan Kasus Fitur Radiografis Ameloblastoma pada CBCT dan Panoramik. *J Kedokt Gigi Univ Padjadjaran.* 2020;32(1):47–51.
- Saifuddin SD, Pramanik F, Firman RN. Analisis ameloblastoma unilokuler menggunakan radiograf cone

- beam computed tomography (CBCT) 3D sebagai penunjang diagnosis. *J Radiol Dentomaksilofasial Indones*. 2020;3(3):33.
7. Merbold LM, Smit CS, Fox JK, Uys AU. The radiologic progression of ameloblastomas. *South African J Radiol*. 2023;27(1):1–8.
 8. Rahmel S, Schulze RKW. Accuracy in Detecting Artificial Root Resorption in Panoramic Radiography versus Tomosynthetic Panoramic Radiographs. *J Endod [Internet]*. 2019;45(5):634–639.e2. <https://doi.org/10.1016/j.joen.2019.01.009>
 9. Ghai S. Ameloblastoma: An updated narrative review of an enigmatic tumor. *Cureus*. 2022;14(8):e27734.
 10. Himammi AN, Hartomo BT. Interpretation of multilocular ameloblastoma and associated radiographic features. *J Radiol Dentomaksilofasial Indones*. 2021;5(1):40–43.
 11. Beder R, Ibrahim M. Minimally invasive approach in the treatment of ameloblastoma in an adolescent: 3-year follow-up. *Tanta Dent J*. 2022;19(4):264.
 12. Omami G. Honeycomb Jaw Lesion: Ameloblastoma. *Ear, Nose Throat J*. 2021;100(7):483–4.
 13. Sargolzaei S, Atarباشi-Moghadam S, Roohi A. Mandibular Mural Ameloblastoma with Unusual Histopathologic Features: a Rare Challenging Case. *J Dent (Shiraz, Iran)*. 2019;20(4):304–7.
 14. Kakuguchi W, Ohiro Y, Nakazawa S, Naito R, Moritani Y, Nakamichi Y, et al. Application of the dredging method in a case of recurrent ameloblastoma that had spread over a large region of the mandible. *J Oral Maxillofac Surg, Med Pathol*. 2020;32(1):44–8. <https://doi.org/10.1016/j.ajoms.2019.09.006>
 15. Cadavid AMH, Araujo JP, Coutinho-Camillo CM, Bologna S, Junior CAL, Lourenço SV. Ameloblastomas: current aspects of the new WHO classification in an analysis of 136 cases. *Surg Exp Pathol*. 2019;2(1):4–9.
 16. Bwambale P, Yahaya JJ, Owor G, Wabinga H. Histopathological patterns and biological characteristics of ameloblastoma: A retrospective cross-sectional study. *J Taibah Univ Med Sci*. 2022;17(1):96–104. <https://doi.org/10.1016/j.jtumed.2021.09.007>
 17. Hu YJ, Cao R, Wang ZH, Hong WS, Zheng CY. Reconstruction of deep circumflex iliac artery free flap for multiple recurrent ameloblastoma in mandible. *J Craniofac Surg*. 2019;30(2):557–62.
 18. Kaneko N, Sameshima J, Kawano S, Chikui T, Mitsuyasu T, Chen H, et al. Comparison of computed tomography findings between odontogenic keratocyst and ameloblastoma in the mandible: Criteria for differential diagnosis. *J Oral Maxillofac Surg, Med Pathol*. 2023;35(1):15–22. <https://doi.org/10.1016/j.ajoms.2022.07.016>
 19. Jackson J, Halim J, Anggraeni R, Sandra F. Bone Resorption in Ameloblastoma and Its Underlying Mechanism. *Indones J Cancer Chemoprevention*. 2021;12(1):57.
 20. Ragunathan YT, Kumar SK, Janardhanam D, Ravi A, Santhanam V, Ramdas MN. Prevalence and Epidemiological Profile of Ameloblastoma in India: A Systematic Review and Meta-Analyses. *Asian Pacific J Cancer Prev*. 2022;23(11):3601–10.
 21. Hendra FN, Van Cann EM, Helder MN, Ruslin M, de Visscher JG, Forouzanfar T, et al. Global incidence and profile of ameloblastoma: A systematic review and meta-analysis. *Oral Dis*. 2020;26(1):12–21.
 22. Hasegawa T, Fukumoto C, Kamimura R, Tsubura Y, Yagisawa S, Izumi S, et al. A case of mandibular bone metastasis of ameloblastoma from the opposite side of the mandible: Immunohistochemical and genetic analyses of clonality. *J Oral Maxillofac Surg, Med Pathol*. 2023;35(6):583–9. <https://doi.org/10.1016/j.ajoms.2023.03.016>
 23. Peter J, Emmatty TB, Jose B, Methippara JJ, Sebastian R, Vasu S. Unicystic Ameloblastoma Associated with Primary Mandibular Second Molar: A Case Report. *Int J Clin Pediatr Dent*. 2023;16(S3):S335–8.
 24. Schoinhoriti O, Tsami C, Karathanasi V, Kolomvos N. Mixed-Pattern Ameloblastoma of the Anterior Mandible: A Rare Histopathological Presentation at an Infrequent Location. *Cureus*. 2023;15(8):6–10.
 25. Jehan R, Shoaib M, Afzal J, Ali M, Noor A, Jamil M, et al. Radiographic Appearance and Root Resorption Caused by Ameloblastoma in pts attending Teaching Institute of Dentistry. *Pakistan J Med Heal Sci*. 2023;17(2):69–72.
 26. Omami G, Adel M. Width-to-length ratio comparison between ameloblastomas and odontogenic keratocysts in the body of the mandible: A preliminary study. *Imaging Sci Dent*. 2020;50(4):319–22.
 27. Ghosh A, Lakshmanan M, Manchanda S, Bhalla AS, Kumar P, Bhatia O, et al. Contrast-enhanced multidetector computed tomography features and histogram analysis can differentiate ameloblastomas from central giant cell granulomas. *World J Radiol*. 2022;14(9):329–41.
 28. Bispo MS, de Queiroz Pierre MLG, Apolinário AL, dos Santos JN, Junior BC, Neves FS, et al. Computer tomographic differential diagnosis of ameloblastoma and odontogenic keratocyst: Classification using a convolutional neural network. *Dentomaxillofac Radiol*. 2021;50(7):1–8.
 29. Nariai Y, Yanai C, Iwahashi T, Kanno T. Clinical features of giant hybrid ameloblastoma of the mandible: A case report with long-term observation of natural growth before treatment. *Oral Maxillofac Surg Cases*. 2019;5(3):100116. <https://doi.org/10.1016/j.omsc.2019.100116>
 30. Luis Sebastián Pinos Pinos, Jorge Antonio Reinoso Ortiz, María Fernanda Torres Calle, Fernando Mauricio Villalta Mendoza. Unicystic ameloblastoma: A literature review. *World J Adv Res Rev*. 2021;10(3):095–103.
 31. Urechescu H, Banu A, Baderca F, Closca RM, Ilas-Tat MB, Urtila F, et al. Ameloblastoma of the Mandible in a 16-Year-Old Female—Case Report. *Med*. 2024;60(1):1–8.
 32. Shi HA, Ng CWB, Kwa CT, Sim QXC. Ameloblastoma: A succinct review of the classification, genetic understanding, and novel molecular targeted therapies. *Surgeon*. 2021;19(4):238–43. <https://doi.org/10.1016/j.surge.2020.06.009>
 33. Goh YC, Siriwardena BSMS, Tilakaratne WM. Association of clinicopathological factors and treatment modalities in the recurrence of ameloblastoma: Analysis of 624 cases. *J Oral Pathol Med*. 2021;50(9):927–36.
 34. Ghai S. Ameloblastoma: An Updated Narrative Review of an Enigmatic Tumor. *Cureus*. 2022;14(8):1–9.
 35. Elmrini S, Raiteb M, Bahaha Razem, Hassani F, Zahra A, Slimani F. Ameloblastoma giant: Diagnosis, treatment, and reconstruction: A case report. *Ann Med Surg*. 2021;68
 36. Bi L, Wei D, Hong D, Wang J, Qian K, Wang H, et al. A retrospective study of 158 cases on the risk factors for recurrence in ameloblastoma. *Int J Med Sci*. 2021;18(14):3326–32.
 37. Kiş Hc, Coşgunarslan A, Cancer Em, Etöz M, Deniz K. Management of Ameloblastoma with Different Imaging Modalities. *Türkiye Klin J Case Reports*. 2020;28(3):145–55.
 38. Martins GG, Oliveira IA, Consolaro A. The mechanism: how dental resorptions occur in ameloblastoma. *Dental Press J Orthod*. 2019 Sep 5;24(4):21–32. doi: 10.1590/2177-6709.24.4.021-032.oim. PMID: 31508703; PMCID: PMC6733230.
 39. More C, Tailor M, Patel HJ, Asrani M, Thakkar K, Adalja C. Radiographic analysis of ameloblastoma: A retrospective study. *J Clin Diagn Res*. 2012;23(5):C05–C08.
 40. Jehan R, Mujtaba H, Noor N, Shoaib M, Noor A, Afzal J, et al. Root resorption in ameloblastoma: a radiographic analysis of 35 cases. *Pak J Med Health Sci*. 2023;17(2):69–72.
 41. Mandlik R, Parihar A, Reddy P, Singh R, Yadav N, Sharma AD. Unveiling radiographic features and radio-pathological correlations of ameloblastoma: A retrospective study. *Arch Med Health Sci*. 2025;(3):370–375. doi:10.4103/amhs.amhs_131.
 42. Garg M, Prakash SMR, Wadhwan V, Nagaraju K, Malik S. Clinico-radiological and Histopathological Correlation of 56 Cases of Ameloblastoma : A 10-Year Retrospective Analysis in North Indian Population. 2017;2(2):2015–8.
 43. Patel S, Saberi N, Pimental T, Teng PH. Present status and future directions: Root resorption. *Int Endod J*. 2022;55(54):892–921.
 44. Siddique AR, Motwani MB, Bankar NJ. Assessment of Digital Intraoral Periapical Radiograph for the Detection of Apical Root Resorption in Inflammatory Periapical Pathologies: A Radiovisiography Study. *Cureus*. 2023;15(9):2–7.
 45. Heboyan A, Avetisyan A, Karobari MI, Marya A, Khurshid Z, Rokaya D, et al. Tooth root resorption: A review. *Sci Prog*. 2022;105(3):1–29.
 46. Abbott P V., Lin S. Tooth resorption—Part 2: A clinical classification. *Dentraumatol*. 2022;38(4):267–85.
 47. Martins GG, de Oliveira IA, Consolaro A. The mechanism: How dental resorptions occur in ameloblastoma. *Dental Press J Orthod*. 2019;24(4):21–32.
 48. Putra PJ, Hartoyo HM, Sim M. Odontogenic Keratocyst finding with Cone Beam Computed Tomography (CBCT): a case report. *J Radiol Dentomaksilofasial Indones*. 2021;5(2):60.
 49. Chai ZK, Mao L, Chen H, Sun TG, Shen XM, Liu J, et al. Improved diagnostic accuracy of ameloblastoma and odontogenic keratocyst on cone-beam CT by artificial intelligence. *Front Oncol*. 2022;12:793417.

- doi:10.3389/fonc.2021.793417
50. Ranchod S, Titinchi F, Behardien N, Morkel J. Ameloblastoma of the mandible: Analysis of radiographic and histopathological features. *J Oral Med Oral Surg.* 2021;27(1):1–8.
 51. Mariz BA, Andrade BA, Agostini M, Almeida OP, Romãnach MJ, Jorge J, et al. Radiographic estimation of the growth rate of initially underdiagnosed ameloblastomas. *Med Oral Patol Oral Cir Bucal.* 2019;24(4):e468–e472. doi:10.4317/medoral.
 52. Galler KM, Grätz EM, Widbilller M, Buchalla W, Knüttel H. Pathophysiological mechanisms of root resorption after dental trauma: a systematic scoping review. *BMC Oral Health.* 2021;21(1):1–14. <https://doi.org/10.1186/s12903-021-01510-6>
 53. Shah DJS, Mathumathi DA. A Clinico-Radiographic (2D&3D) Analysis of Ameloblastoma: With Impacted and Non-Impacted Teeth. *Sch J Dent Sci.* 2021;8(9):276–83.
 54. Abdalla-Aslan R, Friedlander-Barenboim S, Aframian DJ, Maly A, Nadler C. Ameloblastoma incidentally detected in cone-beam computed tomography sialography: A case report and review of the literature. *J Am Dent Assoc.* 2018;149(12):1073–80. <https://doi.org/10.1016/j.adaj.2018.09.003>
 55. Miranda-Viana M, Madlum DV, Oliveira-Santos N, Gaêta-Araujo H, Haïter-Neto F, Oliveira ML. Influence of the image file format of digital periapical radiographs on the diagnosis of external and internal root resorptions. *Clin Oral Investig.* 2021;25(8):4941–8.
 56. Taravati S, Balak Z, Rakhshan V. Diagnostic accuracy of periapical radiography in detection and measurement of the external root resorption in primary molars: a single-blind prospective clinical study. *Int J Dent.* 2022;2022:7031086. doi:10.1155/2022/7031086